

IMAGES AND VIDEOS

Ruptured sinus of Valsalva aneurysm: diagnosis by community echocardiography

Peter J Savill MBBS PGDipCard, Dhrubo J Rakhit PhD FRCP FACC and Benoy N Shah MD FRCP FESC

Department of Cardiology, University Hospital Southampton, Southampton, UK

Correspondence should be addressed to B N Shah: benoy.shah@uhs.nhs.uk

Summary

A 71-year-old man was referred to a general practitioner with specialist interest (GPSI) in cardiology due to exertional breathlessness. Examination revealed a continuous murmur but no signs of heart failure. Echocardiography revealed significant aortic root enlargement (63 mm) with aneurysmal dilatation of the right sinus of Valsalva (Fig. 1A, Video 1) and severe aortic regurgitation (Fig. 1B). Parasternal short-axis images suggested rupture of the aneurysmal right aortic sinus (Fig. 1C, Video 2) with colour Doppler imaging suggestive of a shunt from the aorta into the right atrium (Fig. 1D, Video 3). The study was uploaded to a cloud-based server (Ultralingq Healthcare Solution Inc, New York, USA) and the GPSI contacted the local tertiary centre urgently. On image review, the suspicion was confirmed of an aorto-atrial fistula secondary to the ruptured sinus of Valsalva aneurysm and the patient was hospitalized the same day. At surgery, the aortic root had significantly thinned walls in all sinuses with the presence of a large aneurysm extending from the right coronary sinus towards the right ventricular outflow tract. The fistulous communication was identified and led into the right atrium – this was repaired with pledgeted sutures. A modified Bentall procedure was performed, with a 27 mm Perimount, bioprosthesis sewn into a 34 mm Valsalva Gelweave graft for the aortic root replacement. Sinus of Valsalva aneurysm is a rare abnormality (population incidence 0.09%) that occurs due to a weakening of the layers of the aortic wall (principally the aortic media). This may be due to a congenital abnormality in the aortic wall or may be acquired following bacterial endocarditis or connective tissue disorders. Most aneurysms arise from the right coronary sinus and at least 1/3 will rupture. Rupture into the right heart chambers can lead to a significant intra-cardiac shunt and acute heart failure. In recent years,

there has been a significant expansion of community cardiology clinics, including the provision of echocardiography. The method of storage of echocardiographic studies is variable – this case highlights not just the potential value of skilled community echocardiography operators but also the value of cloud-based servers that can facilitate rapid expert review of images performed remotely so that timely management decisions can be made.

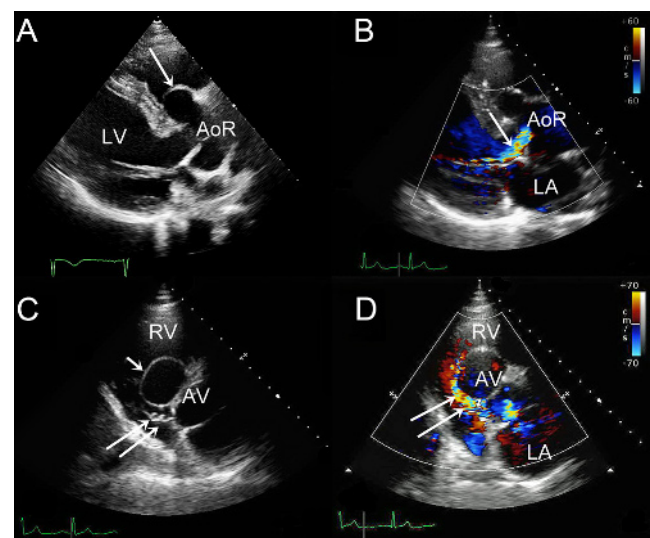


Figure 1
(A) Parasternal long axis view showing a thin and aneurysmal right sinus of the aortic root (arrow). (B) Parasternal long axis with colour Doppler imaging revealing central aortic regurgitation (arrow). (C) Parasternal short axis view showing evidence of the dilated right sinus (single arrow) with evidence of rupture and fistula formation into the right atrium (double arrows). (D) Parasternal short axis with colour Doppler imaging demonstrating flow from the aorta into the right heart (LA, left atrium; LV, left ventricle; AV, aortic valve; RV, right ventricle; AoR, aortic root).

Video 1

Parasternal long axis view with a dilated aortic root and colour Doppler imaging demonstrating aortic regurgitation. View Video 1 at <http://movie-usa.glencoesoftware.com/video/10.1530/ERP-20-0020/video-1>.

Video 2

Parasternal short axis view suggestive of a ruptured sinus of Valsalva aneurysm (arrows). (RA, right atrium; RV, right ventricle; LA, left atrium; TV, tricuspid valve; AV, aortic valve.) View Video 2 at <http://movie-usa.glencoesoftware.com/video/10.1530/ERP-20-0020/video-2>.

Video 3

Parasternal short axis view with colour Doppler imaging suggesting abnormal flow (i.e. rupture) from the aorta

towards the right heart chambers (arrows). View Video 3 at <http://movie-usa.glencoesoftware.com/video/10.1530/ERP-20-0020/video-3>.

Declaration of interest

The authors declare that there is no conflict of interest that could be perceived as prejudicing the impartiality of this article.

Funding

This work did not receive any specific grant from any funding agency in the public, commercial or not-for-profit sector.

Patient consent

Signed patient consent form provided.

Received in final form 10 July 2020

Accepted 11 November 2020

Accepted Manuscript published online 11 November 2020