

RESEARCH ARTICLE

Open Access



Expression patterns of ciliopathy genes *ARL3* and *CEP120* reveal roles in multisystem development

L. Powell^{1†}, M. Barroso-Gil^{1†}, G. J. Clowry², L. A. Devlin¹, E. Molinari¹, S. A. Ramsbottom¹, C. G. Miles¹ and J. A. Sayer^{1,3,4*} 

Abstract

Background: Joubert syndrome and related disorders (JSRD) and Jeune syndrome are multisystem ciliopathy disorders with overlapping phenotypes. There are a growing number of genetic causes for these rare syndromes, including the recently described genes *ARL3* and *CEP120*.

Methods: We sought to explore the developmental expression patterns of *ARL3* and *CEP120* in humans to gain additional understanding of these genetic conditions. We used an RNA in situ detection technique called RNAscope to characterise *ARL3* and *CEP120* expression patterns in human embryos and fetuses in collaboration with the MRC-Wellcome Trust Human Developmental Biology Resource.

Results: Both *ARL3* and *CEP120* are expressed in early human brain development, including the cerebellum and in the developing retina and kidney, consistent with the clinical phenotypes seen with pathogenic variants in these genes.

Conclusions: This study provides insights into the potential pathogenesis of JSRD by uncovering the spatial expression of two JSRD-causative genes during normal human development.

Keywords: CEP120, ARL3, Foetus, Development, Retina, Kidney, Brain, RNAscope

Background

Joubert syndrome and related disorders (JSRD) are a group of autosomal inherited ciliopathies that are characterised as a cerebello-retinal-renal phenotype, and have an incidence rate of 1:80,000–100,000 live births [1–3]. The hallmark brain phenotype is a “molar tooth sign” shown on axial brain MRI, caused by cerebellar vermis hypoplasia and other mid and hindbrain

malformations [4]. These defects often cause symptoms of hypotonia, ataxia and intellectual disability in patients [5]. The retinal and renal phenotypes associated with JSRD have a lower incidence rate and vary in severity. Renal disorders occur in ~25% of patients, often presenting as corticomedullary cysts, interstitial fibrosis, or tubulointerstitial kidney disease [5]. The renal component is progressive and can lead to end-stage renal disease [6]. Ocular phenotypes of retinitis dystrophy, retinitis pigmentosa, oculomotor apraxia, and ptosis are common in patients, and as with the renal aspects of JSRD are often progressive in nature [7].

Currently, there are more than 35 genes that are known to cause JSRD (<https://www.omim.org/phenotypicSeries/PS213300>). The syndrome is caused by defects

* Correspondence: john.sayer@newcastle.ac.uk

[†]Powell L and Barroso-Gil M are joint first authors

¹L. Powell and M. Barroso-Gil contributed equally to this work.

¹Translational and Clinical Research Institute, Newcastle University, Central Parkway, Newcastle upon Tyne NE1 3BZ, UK

³The Newcastle Hospitals NHS Foundation Trust, Freeman Road, Newcastle upon Tyne NE7 7DN, UK

Full list of author information is available at the end of the article



© The Author(s). 2020 **Open Access** This article is licensed under a Creative Commons Attribution 4.0 International License, which permits use, sharing, adaptation, distribution and reproduction in any medium or format, as long as you give appropriate credit to the original author(s) and the source, provide a link to the Creative Commons licence, and indicate if changes were made. The images or other third party material in this article are included in the article's Creative Commons licence, unless indicated otherwise in a credit line to the material. If material is not included in the article's Creative Commons licence and your intended use is not permitted by statutory regulation or exceeds the permitted use, you will need to obtain permission directly from the copyright holder. To view a copy of this licence, visit <http://creativecommons.org/licenses/by/4.0/>. The Creative Commons Public Domain Dedication waiver (<http://creativecommons.org/publicdomain/zero/1.0/>) applies to the data made available in this article, unless otherwise stated in a credit line to the data.

of the primary cilia, which are found on most mammalian cells [8]. Primary cilia act as a cellular antenna to transduce extracellular signals such as mechanical flow, chemical stimulation, and key signalling pathways (including Hedgehog, Wnt, and PDGF) into the cell [9–13]. Due to the multi-organ involvement, varying phenotypes, and multitude of genes known to cause JSRD there is great heterogeneity within the syndrome and overlap with closely related ciliopathies including Bardet-Biedl syndrome (<https://omim.org/phenotypicSeries/PS209900>) and Jeune syndrome (<https://omim.org/phenotypicSeries/PS208500>) [14]. Recently discovered genetic causes of JSRD include *ARL3* [15] and *CEP120* [16, 17]; the fact that their encoded proteins have such divergent roles within the primary cilium demonstrates the complexity underlying this group of related disorders.

ADP-ribosylation factor-like 3 (*ARL3*), a RAS superfamily member, is a low molecular weight GTP-binding protein [18] that cycles between inactive GDP-bound and active GTP-bound states to release cargo from their carriers in the cilium [19]. *ARL3* interacts with its Guanine Exchange Factor *ARL13B* in the cilium [20] and GTPase Activating Protein *RP2* at the basal body of the cell [21, 22]. *Arl3* knockout studies in mice demonstrate a multi-organ ciliopathy phenotype, including kidney cysts, liver fibrosis and retinal disease with photoreceptor cell degeneration [23–26]. Recently, two families affected by JSRD have been identified, presenting with ciliopathy phenotypes [15]. The underlying genetic cause was shown to be missense mutations in *ARL3*, which affect an amino acid residue involved in the interaction between *ARL3* and *ARL13B* [15].

Centrosomal protein of 120 kDa (*CEP120*) is a centrosomal protein involved in centriole biogenesis, including centriole duplication, assembly [27, 28], elongation [29–31] and maturation [28]. *CEP120* also interacts with other centrosomal proteins including *CPAP* [29, 30], *SPICE1* [29], *Talpid3* [28, 31] and *C2CD3* [31]. *CEP120* was found to be expressed ubiquitously in murine embryonic tissues such as the brain, kidney and lungs. Additionally, *Cep120* was observed to be highly expressed in embryonic mouse brain compared to postnatal or adult mouse brain [32]. Inactivation of *CEP120* in the mouse central nervous system results in hydrocephalous and cerebellar hypoplasia [28]. *CEP120* mutations have been shown to cause JSRD and Jeune syndromes [16, 17], and overlapping ciliopathy phenotypes such as tectocerebellar dysraphia with occipital encephalocele (TCDOE), Meckel syndrome (MKS) and oro-facial-digital (OFD) syndromes [17].

The developmental expression patterns of *ARL3* and *CEP120* in humans is not known. In order to explore this, we used an RNA in situ detection technique called

RNAscope to compare and contrast the developmental spatial expression of these new and divergent causes of JSRD. We successfully characterised *ARL3* and *CEP120* expression patterns in human embryos and foetuses in collaboration with the MRC-Wellcome Trust Human Developmental Biology Resource (HDBR). This study provides insights into the potential pathogenesis of JSRD by uncovering the expression pattern of two JSRD-causative genes during normal human development.

Methods

RNAscope studies

Characterisation of *ARL3* and *CEP120* expression patterns was performed in human embryonic tissue using samples obtained from the MRC-Wellcome HDBR. Formalin fixed paraffin embedded sections of human embryonic and foetal tissue were prepared using 10% neutral buffered formalin and fixed for 32 h at room temperature. Samples were then prepared for the RNAscope assay, a RNA in situ detection platform for detection of target RNA within intact cells, as per manufacturers' instructions [33, 34]. An RNAscope 2.5 Assay RED was employed with 20 paired probes across nucleotides 169–1570 (NM_004311.3) and 115–1133 (NM_001166226.1) for detection of *ARL3* and *CEP120*, respectively and counterstained with Methyl Green.

Whole human embryo sections of 8 post-conception weeks (PCW), (equivalent to Carnegie Stage 23) were analysed, along with hindbrain (14PCW and 19PCW), eye (14PCW), kidney and adrenal gland (14PCW and 18PCW). A negative RNAscope 2.5 HD Assay Red control (*dapB*, a bacterial gene which is not expressed in human tissues) was performed (Supplementary Figure 1). In addition, the RNAscope 2.5 HD Assay RED was performed with a positive control (*KI67*, a cell proliferation marker). *KI67* is a nuclear protein commonly used as a proliferation marker, which is expressed in cycling cells and is associated with cellular proliferation. It is encoded by the gene marker of proliferation *Ki-67*, *MKI67*. *ARL3* and *CEP120* human expression patterns were analysed using the HDBR image server (Leica Biosystems).

Clinical phenotypes and sequence analysis

Reported clinical phenotypes associated with *ARL3* and *CEP120* mutations were reviewed within OMIM (<https://omim.org/>). Putative *Arl3* and *Cep120* orthologues were identified using BLASTP, with human *ARL3* (isoform a, NP_004302.1) and *CEP120* (NP_694955.2) transcripts as the query sequences within NCBI (<https://www.ncbi.nlm.nih.gov/>). Additional databases including Flybase (<https://flybase.org/>), Wormbase (<https://www.wormbase.org/>) and Phytozome (<https://phytozome.jgi.doe.gov/>) were also queried using BLAST.

Results

Clinical phenotypes of ARL3 and CEP120 patients

Biallelic mutations in both *ARL3* and *CEP120* mutations are rare causes of ciliopathy syndromes. A comparison of the known phenotypes associated with *ARL3* and *CEP120* mutations is shown in Table 1. This overview reveals that mutations in *CEP120* are at present associated with severe phenotypes including MKS but also that single heterozygous changes in *ARL3* are sufficient to cause retinal-limited phenotypes. *ARL3* is highly conserved, with homologs present in *C. elegans*, *C. reinhardtii* and *D. melanogaster* whereas *CEP120* appears not to have homologs within these lower organisms (Supplementary Table 1). Known protein localisation within the cell of both *ARL3* within the ciliary axoneme, and *CEP120* in the centrosomes, are consistent with their role in ciliopathy syndromes (Supplementary Table 2).

ARL3 and CEP120 are expressed in early human brain development

In 8PCW human brain tissue, the expression of *ARL3* and *CEP120* is remarkably similar. There is expression of both genes in the choroid plexus (Fig. 1Ai and 1Bi), which appears to favour the luminal facing surface of the tissue, especially for *ARL3*. The cell proliferation marker *KI67* does not share this same expression pattern in the choroid plexus (Fig. 1Ci). This specific expression

pattern of *ARL3* and *CEP120* in luminal-facing cells is continued throughout the developing brain where both genes exhibit expression throughout the ventricular zone of the ganglionic eminences, cortical wall, and the hind-brain including the rhombic lip (Fig. 1Aii-Aiv and 1Bii-Biv). There is specific expression of *ARL3* and *CEP120* in the layer of cells forming the apical surface in each tissue, facing into the ventricular space. Expression of *KI67* is seen throughout these tissues (Fig. 1Cii-Civ), with specific expression in the apical layer consistent with this being the major site of cell division (cells in G2/M1 phase of cell cycle) in the ventricular zone [37].

Expression of ARL3 and CEP120 is maintained in the developing cerebellum

In the human cerebellum at 14PCW there is expression of *ARL3* and *CEP120*. Both genes have strong expression in the external and internal granule cell layer (EGL and IGL) the developing cerebellum (Fig. 2Ai and Ci). Expression in the EGL and IGL is seen at 19PCW for *ARL3* (Fig. 2Bi) however, *CEP120* expression is predominantly localised in the EGL and the molecular layer (ML) of the cerebellum at 19PCW (Fig. 2Di). Strong expression of *KI67* is seen throughout the EGL in particular, but also the IGL at 19PCW, indicating the tissue is proliferative (Fig. 2Ei). *ARL3* and *CEP120* are therefore widely expressed in the cerebellum during development, with specific expression of *CEP120* in the ML which is

Table 1 Comparison of the known phenotypes associated with *ARL3* and *CEP120* mutations

	Patients with <i>ARL3</i> related ciliopathy	Patients with <i>CEP120</i> related ciliopathy
Number of affected patients reported and presenting phenotypes	4 patients reported with JSRD secondary to biallelic changes [15] 4 patients with retinitis pigmentosa secondary to monoallelic changes [35, 36]	4 patients with JSRD 4 patients with JATD 1 foetus with MKS 1 foetus with TCDOE [16, 17]
Brain imaging findings	Molar tooth sign	Molar tooth sign
Intellect	Developmental delay Psychomotor delay	Developmental delay Cognitive impairment
Skeletal	No known associated phenotypes	Severely narrow chest Skeletal dysplasia Small and horizontal ribs Short limbs Polydactyly Synpolydactyly
Mobility	Ataxic gait Hypotonia	Truncal ataxia Hypotonia
Eye	Night blindness Bilateral vision loss Retinal dystrophy Ocular motor apraxia	Microphthalmia Duane syndrome Strabismus
Kidney	Cystic dysplastic kidney Bilateral renal scarring Recurrent urinary tract infections	Cystic dysplastic kidney

JSRD Joubert syndrome and related disorders; *JATD* Jeune asphyxiating thoracic dystrophy; *MKS* Meckel syndrome; *TCDOE* tectocerebellar dysraphia with occipital encephalocele

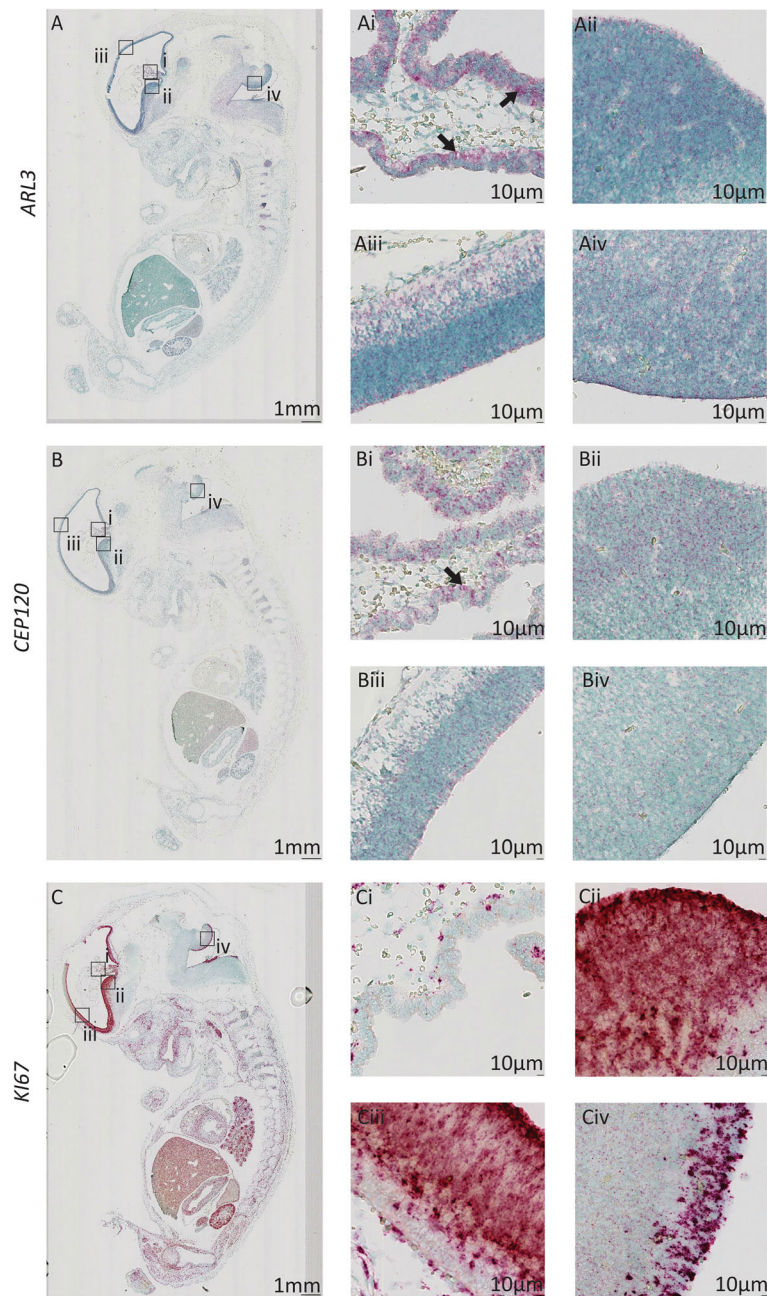


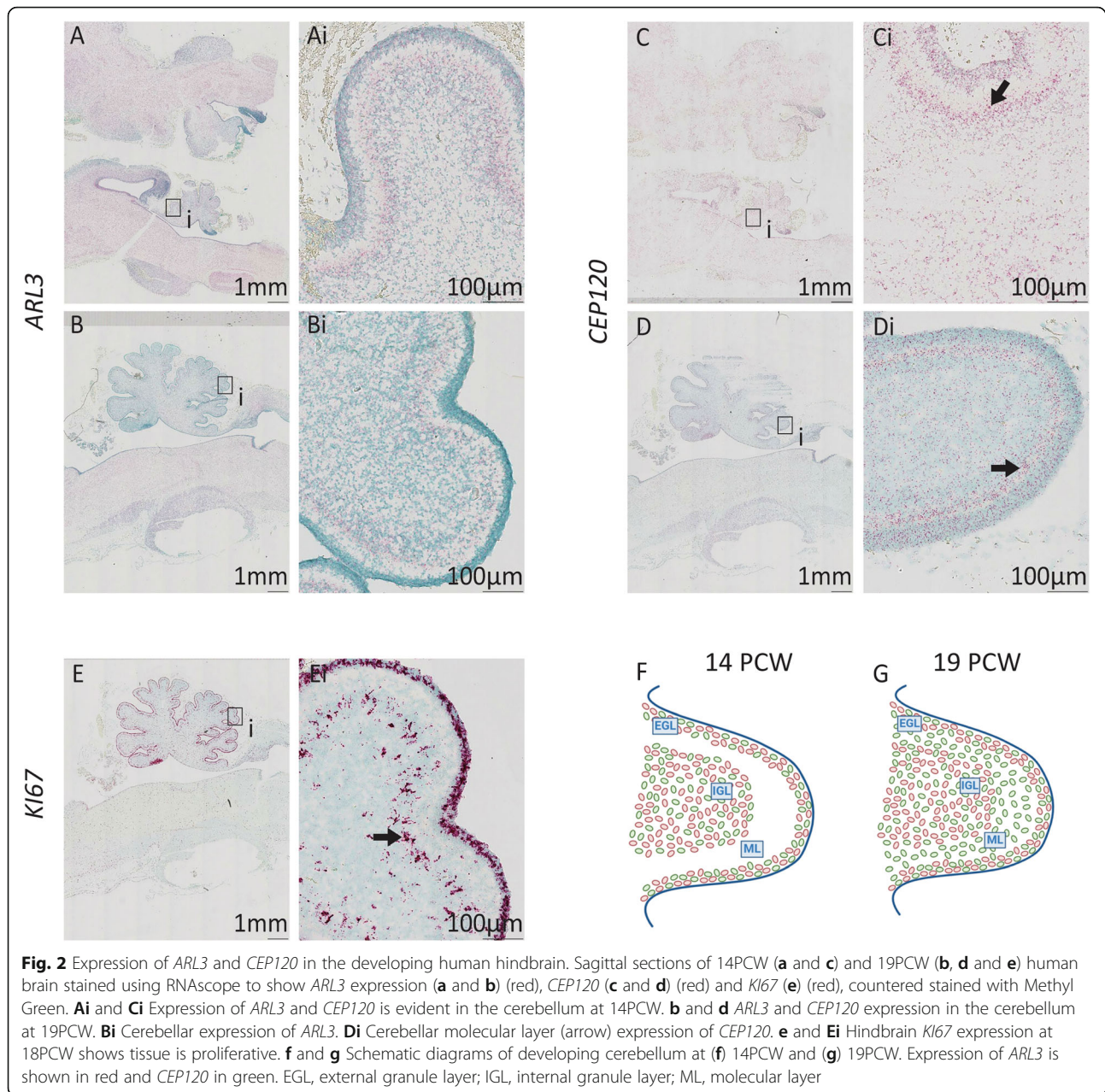
Fig. 1 Expression pattern of *ARL3* and *CEP120* in the human brain during early development. Sagittal sections of 8PCW-stage human embryos stained using RNAscope to show expression of *ARL3* (a) (red), *CEP120* (b) (red) and *KI67* (c) (red), counterstained with Methyl Green. **Ai** and **Bi** *ARL3* and *CEP120* are expressed within cells of the choroid plexus (arrow). **(Ci)** *KI67* expression is minimal in the choroid plexus. **Aii-Aiv** and **(Bii-Biv)** Expression of *ARL3* and *CEP120* is seen in the ventricular radial glia progenitor cells including the ventricular zone of the ganglionic eminences (**Aii** and **Bii**), cerebral cortex (**Aiii** and **Biii**), and rhombic lip (**Aiv** and **Biv**). **Cii-Civ** Expression of *KI67* is seen in the ventricular zone of the ganglionic eminences, cerebral cortex, and hindbrain

predominantly occupied by the dendritic trees of Purkinje cells and the interacting parallel fibres of granule cells. As dendrites and axons contain low levels of mRNA, it is likely that *CEP120* expression is predominantly located in the sparse population of interneurons found in the molecular layer [38] or in immature granule

cells migrating from EGL to IGL [39] suggesting a role for *CEP120* in these cell types [38].

Expression of *ARL3* and *CEP120* in the developing eye

The human retina can be divided into nine layers based upon the cell types that occupy each layer



(Fig. 3a), with the retinal pigment epithelial (RPE) and photoreceptor layers at the outermost part of the eye [39]. At 8PCW, the retinal layers are not well defined with only a ganglion cell layer separated from a layer of mostly immature neuroblasts with a few photoreceptor cells by a thin inner plexiform layer [40]. At this stage *ARL3* and *CEP120* show expression throughout the developing retina, with high expression within the retinal ganglion cells and the photoreceptor layer (Fig. 3Bi and Di). At 14PCW, the retinal layers are maturing [39] which is reflected in the expression pattern of both *ARL3* and *CEP120*. Clear expression of both genes is still seen in all

layers of the retina, although to a lesser extent in the plexiform and nerve fibre layers due to reduced cell density in these areas (Fig. 3Ci and Ei).

Expression of *ARL3* and *CEP120* in the developing dorsal root ganglia

The dorsal root ganglia are formed by migrating neural crest cells and contain most of the body's sensory neurones [42, 43]. Both *ARL3* and *CEP120* show expression in cells of the dorsal root ganglia, which are post-mitotic primary sensory neurones (Fig. 4 Ai-Aii and Bi-Bii). There is strong expression of *KI67* within limited

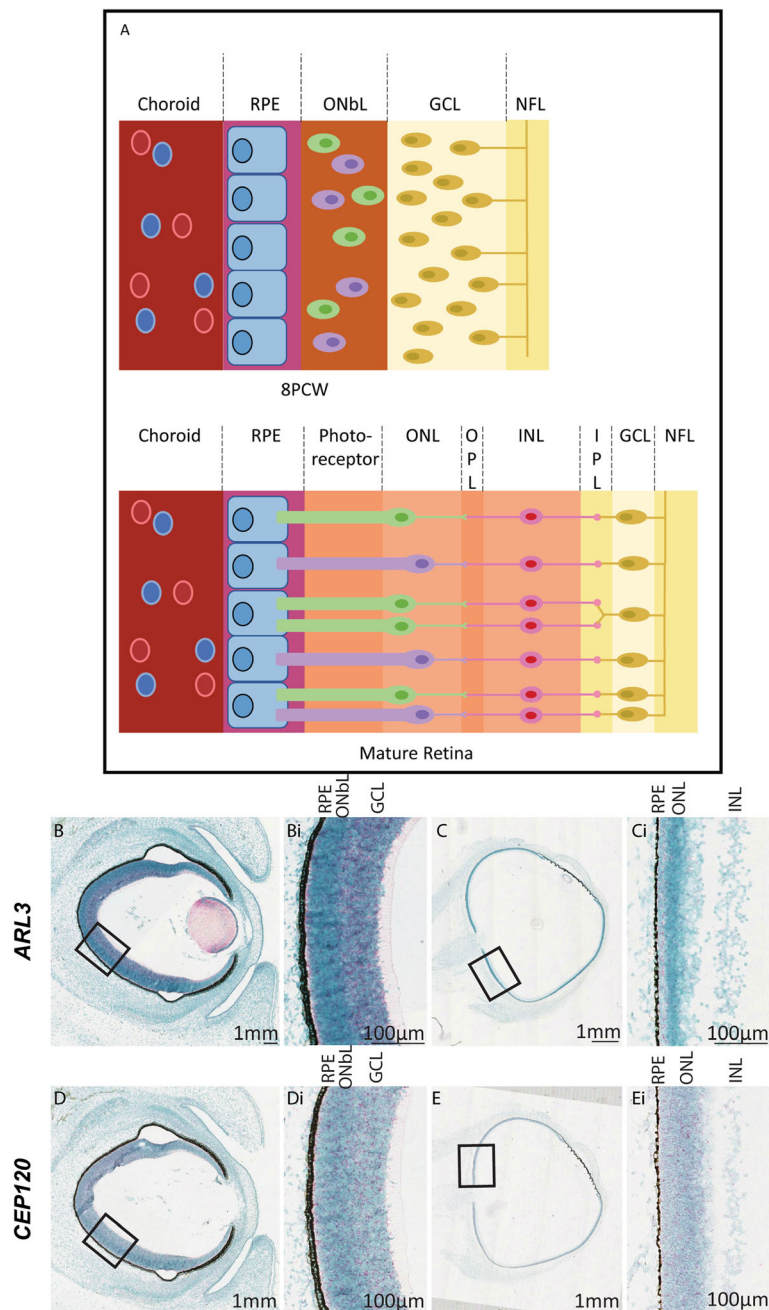


Fig. 3 Expression of *ARL3* and *CEP120* in the developing human retina. **a** Schematic diagram of the development of the layers of the retina from 8PCW to the mature form (adapted from [40]). At 8PCW, not all of the layers are present in the retina. The ONbL is a transitional layer containing retinal progenitor cells that will develop into various cell types such as photoreceptors, amacrine and bipolar cells; separating into the ONL, OPL, INL, and IPL (the IPL is sometimes visible at 8PCW). The GCL is thicker at 8PCW due to the migration of cells. The mature retina can be divided into layers. The RPE is at the very back of the eye and assists in the removal of waste products from the photoreceptor cells, which transduce light. The ONL, OPL, INL and IPL layers house intermediary cell bodies and dendrites that interact with ganglion cells in the GCL to convey the signal through the optic nerve, formed in the NFL, to the brain (reviewed in [41]). **b** Human sections of developing eye at 8PCW (**b** and **d**) and 14PCW (**c** and **e**) stained using RNA Scope to show *ARL3* expression (**b** and **c**) (red) and *CEP120* (**d** and **e**) (red) counterstained with Methyl Green (**Bi** and **Di**). There is a gradient of *ARL3* (**Bi**) and *CEP120* (**Di**) expression in the retina at 8PCW across multiple retinal layers including the ONbL. At 14 PCW, *ARL3* (**Ci**) and *CEP120* (**Ei**) expression is localised across multiple layers including the photoreceptor cell layer, just below the RPE layer (arrows). GCL, ganglion cell layer; INL, inner nuclear layer; IPL, inner plexiform layer; NFL, nerve fibre layer; ONL, outer nuclear layer; OPL, outer plexiform layer; ONbL, outer neuroblastic layer; RPE, retinal pigment epithelium

number of cells in the dorsal root ganglia, presumably non-neuronal (Fig. 4 Ci-Cii).

Expression of *ARL3* and *CEP120* in the developing kidney

In the developing human kidney at 8PCW, where there is strong renal cortical staining of *KI67* indicating cell proliferation (Supplementary Figure 2), there is expression of *ARL3* in cells within the developing cortical nephrons; this expression appears to be specifically oriented to the lumen of the structures (Fig. 5Ai). This expression pattern is maintained at 14PCW (Fig. 5Bi) and 18PCW (Fig. 5 Ci). Expression of *CEP120* is also seen in developing nephrons at 8PCW, however there is also expression in the renal cortex (Fig. 5Di). This expression pattern of *CEP120* is maintained at 14PCW (Fig. 5Ei) and 18PCW, although overall expression appears to have decreased at this time point (Fig. 5Fi).

Expression of *ARL3* and *CEP120* in other major organs

In the developing human heart, lung and gut at 8PCW, there is very low levels of expression of *ARL3* and *CEP120* (Supplementary Figure 3). Expression of *ARL3* and *CEP120* is seen around the developing alveoli and at low levels in the developing bowel epithelia. The remaining organs of the developing embryo did not reveal prominent expression patterns.

Discussion

Mutations in *ARL3* and *CEP120* are rare and relatively new causes of JSRD and other related ciliopathies. Human protein atlas data suggests that tissue expression of *ARL3* protein is widely expressed, with highest expression scores seen in cerebellum and lowest in heart and skeletal muscle (<https://www.proteinatlas.org/ENSG00000138175-ARL3/tissue>). RNA expression is high in cerebral cortex, cerebellum, retina and kidney consistent with its known phenotypes. *CEP120* protein expression is not annotated within the human protein atlas, whereas RNA is strongly expressed in the cerebellum (<https://www.proteinatlas.org/ENSG00000168944-CEP120/tissue>). We aimed to define expression of *ARL3* and *CEP120* during human development using the HDBR tissue bank employing a relatively new in situ hybridisation assay called RNAscope for the detection of target RNA within intact cells. We used *KI67* as a positive control although we recognise that expression of *KI67* is not homogeneous throughout each tissue. Our data provide an insight into the developmental expression of *ARL3* and *CEP120*. We show that both of these genes are expressed in key tissues (including retina, cerebellum and kidney) during development. This expression pattern fits with the multisystem disease phenotypes seen in patients with *ARL3* and *CEP120* mutations (Table 1). A similar approach, using the valuable HDBR tissue bank has been performed, using in situ hybridisation for

studying the expression of *ARL13B* [44], another cause of Joubert syndrome. Here *ARL13B* was detected at stage CS16 in the alar and basal plate of the myelencephalon, the mesencephalon and the metencephalon. At CS19 *ARL13B* was seen in the ventricular layer of the diencephalon and myelencephalon, the tegmentum of the pons and the cerebellar rhombic lips as well as the dorsal root ganglia. This pattern of expression is remarkably similar to the *CEP120* and *ARL3* data described here.

Expression of both *ARL3* and *CEP120* was minimal in developing cardiac, lung and gut tissues, consistent with lack of known phenotypes affecting these organ systems (Supplementary Figure 3). *ARL3* and *CEP120* encode proteins that are expressed in the primary cilia and basal body respectively (Supplementary Table 2) and pathogenic variants result in similar and overlapping phenotypes, including the cerebello-retinal-renal syndrome JSRD (Table 1). The number of patients with pathogenic variants in either *ARL3* or *CEP120* remains small, allowing a limited comparison of phenotypes, although skeletal manifestations (in particular short ribs/asphyxiating thoracic dystrophy phenotypes) seen in patients with *CEP120* mutations have not been documented in patients with *ARL3* mutations.

There were notable differences in evolutionary conservation between *ARL3* and *CEP120* (Supplementary Table 1). The *ARL3* human protein shares greater than 90% identity with its two orthologous sequences (there is genomic duplication of *arl3* in *Danio rerio* (zebrafish), a well-studied model species in vertebrates. In contrast, *CEP120* human protein only shares 57% identity with its single orthologous sequence found in zebrafish. Moreover, human *ARL3* protein shares >60% identity with its orthologues found in *Drosophila melanogaster*, *Caenorhabditis elegans* and *Chlamydomonas reinhardtii*. *CEP120* is conserved in some vertebrate organisms but orthologues were not readily identified in invertebrates. There is a putative *CEP120* orthologue, UNI2, found in *Chlamydomonas reinhardtii*, but this has not as yet been confirmed as a functional ortholog [27, 44]. *ARL3* is described in diverse eukaryotic organisms such as *Leishmania donovani* [45] and *Caenorhabditis elegans* [46] [47] where it has a functional role in the cilium/flagella. Despite these differences in evolutionary conservation, our results show that *ARL3* and *CEP120* have similar expression patterns during human development, specifically in the eye and dorsal root ganglia as well as during early brain development. Both genes are expressed throughout the retina during development, with expression in the RPE and photoreceptor layers, suggesting a role for both genes during retinal development. This is further supported by the numerous retinal phenotypes associated with mutations in *ARL3* [15–17]. Similarly, the specific expression of *ARL3* and *CEP120* in

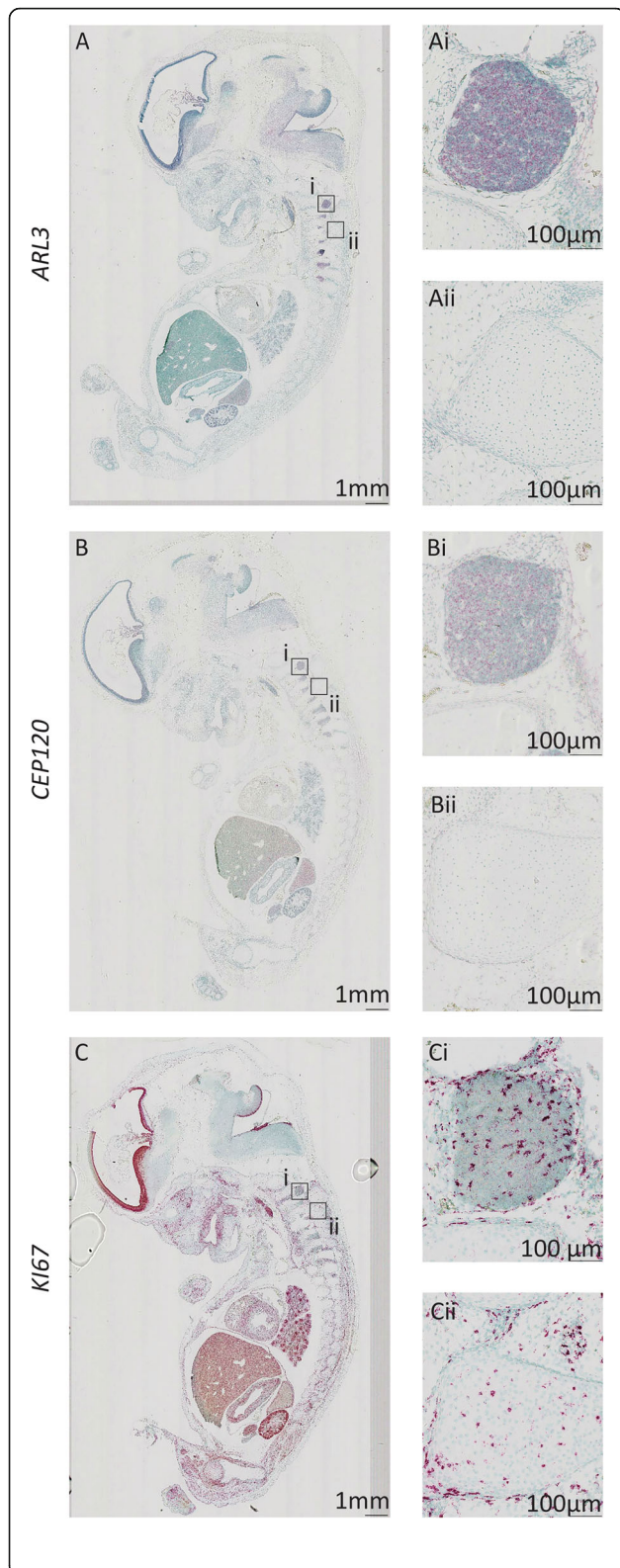


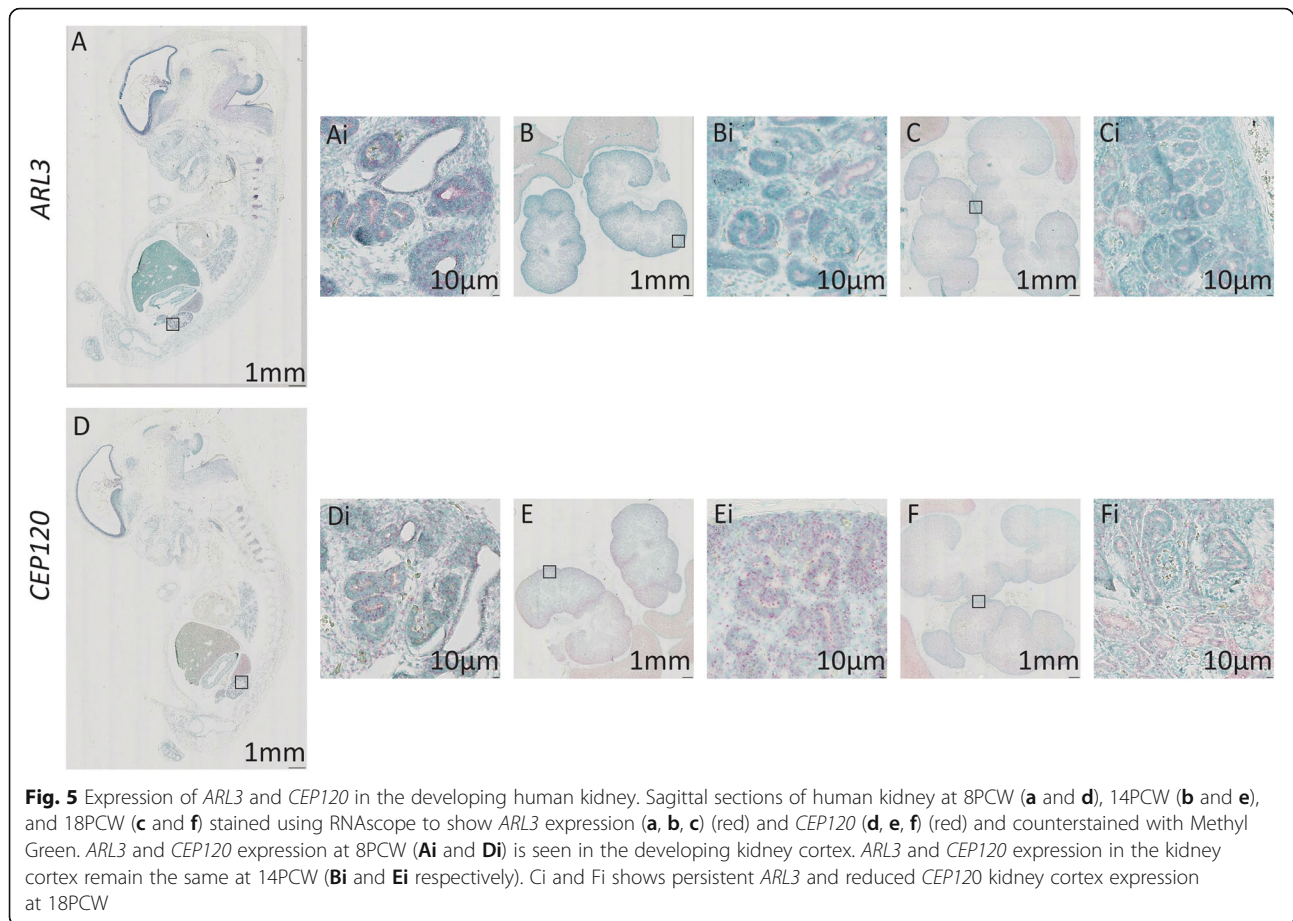
Fig. 4 Expression of *ARL3* and *CEP120* in the developing human dorsal root ganglia Sagittal sections of 8PCW human embryos stained using RNAscope to show expression of *ARL3* (a) (red), *CEP120* (b) (red) and *KI67* (c) (red) counterstained with Methyl Green. *ARL3* and *CEP120* expression is shown within the dorsal root ganglia (Ai and Bi respectively), whereas surrounding tissue has low level expression of these genes (Aii and Bii). *KI67* expression is seen in the dorsal root ganglia (Ci) and surrounding tissues (Cii)

the dorsal root ganglia hints at a role for both genes in primary sensory neurone differentiation. A recurring pattern was the expression of both mRNAs on the luminal facing surface of the cerebral tissue (seen in the choroid plexus and ventricular zones of the cerebral cortex ganglionic eminences, and hindbrain) which could suggest a sensory role for the gene products of both the genes within the cilium of the ventricular lining of the brain.

Expression of *ARL3* and *CEP120* changes during development notably in the cerebellum and kidney. *ARL3* and *CEP120* are expressed throughout the cerebellum at 14PCW however, at 19PCW, *ARL3* expression was predominantly in the IGL whereas *CEP120* was expressed in the EGL and ML of the cerebellum. This could imply that *ARL3* and *CEP120* are expressed in different cell populations of the cerebellum, *ARL3* in both immature and mature granule cells, and *CEP120* in immature, migratory granule cells and ML interneurons [48]. It has been previously reported in mouse studies that *Cep120* is required for proliferation of cerebellar neural progenitor cells [28] and is required for correct development of the embryo. Taken with these results, it suggests that *CEP120* expression is required for correct development of the cerebellum in humans.

Expression of *ARL3* and *CEP120* also differed in the developing kidney. The results showed that *ARL3* was specifically expressed in cells of the nephrons whereas *CEP120* was expressed in the nephrons as well as within cells in the developing renal cortex. This difference in expression could imply that *ARL3* has a more sensory/signalling function in luminal structures of the kidney, whereas *CEP120* has a more universal role in all cells as it is expressed more ubiquitously throughout the tissue.

The differences in gene expression may reflect the divergent functions of *ARL3* and *CEP120* proteins (Supplementary Table 2). As *ARL3* is a trafficking protein involved in ciliary signalling [19, 49], it may only be expressed in actively signalling cells during certain points in development such as nephron progenitors and cells in the IGCL. In contrast, *CEP120* is involved in building the centriole, and therefore cilium, [27, 29] and so will be expressed more widely within tissues, especially those with ciliated epithelia [50, 51].



In conclusion, we establish in human embryonic tissue expression patterns of *ARL3* and *CEP120* during development and provide insights into the wide phenotypic spectrum of mutations affecting *ARL3* and *CEP120* in humans. These studies will allow further investigations into tissue-specific mechanistic roles of *ARL3* and *CEP120* in human health and disease.

Supplementary Information

The online version contains supplementary material available at <https://doi.org/10.1186/s12861-020-00231-3>.

Additional file 1.

Abbreviations

EGL: External granule cell layer; GCL: Ganglion cell layer; HDBR: Human Developmental Biology Resource; IGL: Internal granule cell layer; INL: Inner nuclear layer; IPL: Inner plexiform layer; JATD: Jeune asphyxiating thoracic dystrophy; JSRD: Joubert syndrome and related disorders; MKS: Meckel syndrome; ML: Molecular layer; NFL: Nerve fibre layer; OFD: Oro-facial-digital; ONbL: Outer neuroblastic layer; ONL: Outer nuclear layer; OPL: Outer plexiform layer; PCW: Post-conception weeks; RPE: Retinal pigment epithelium; TCDOE: Tectocerebellar dysraphia with occipital encephalocele

Acknowledgements

Schematic diagrams were created using [Biorender.com](https://biorender.com)

Authors' contributions

LP and MB-G analysed and interpreted the data regarding the RNA expression studies. GJC, LAD, SAR and CGM performed data analysis and contributed in writing the manuscript. JAS conceived the project. All authors read and approved the final manuscript.

Funding

LP is funded by the Medical Research Council Discovery Medicine North Training Partnership. MB-G is funded by Kidney Research UK (ST_001_20171120) and Northern Counties Kidney Research Fund. EM is funded by Kidney Research UK (Paed_RP_20180925). SAR is Kidney Research UK post-doctoral fellow (PDF_003_20151124). CGM and JAS are funded by Kidney Research UK and Northern Counties Kidney Research Fund. The funding bodies had no role in the design of the study and collection, analysis, and interpretation of data nor in the writing of the manuscript.

Availability of data and materials

All data generated or analysed during this study are included in this published article and its supplementary information files. The datasets used and/or analysed during the current study are available from the corresponding author on reasonable request.

Ethics approval and consent to participate

This study was conducted with full ethical approval. For human embryonic and foetal tissue samples, the samples were collected with appropriate written maternal consents and ethical approval by the Newcastle and North Tyneside 1 Research Ethics Committee, UK.

Consent for publication

Not applicable.

Competing interests

The authors declare that they have no competing interests.

Author details

¹Translational and Clinical Research Institute, Newcastle University, Central Parkway, Newcastle upon Tyne NE1 3BZ, UK. ²Biosciences Institute, Newcastle University, Framlington Place, Newcastle upon Tyne NE2 4HH, UK. ³The Newcastle Hospitals NHS Foundation Trust, Freeman Road, Newcastle upon Tyne NE7 7DN, UK. ⁴National Institute for Health Research Newcastle Biomedical Research Centre, Newcastle upon Tyne NE4 5PL, UK.

Received: 27 July 2020 Accepted: 11 November 2020

Published online: 09 December 2020

References

- Malicdan MC, Vilboux T, Stephen J, Maglic D, Mian L, Konzman D, et al. Mutations in human homologue of chicken talpid3 gene (KIAA0586) cause a hybrid ciliopathy with overlapping features of Jeune and Joubert syndromes. *J Med Genet.* 2015;52(12):830–9.
- Travaglini L, Brancati F, Silhavy J, Iannicelli M, Nickerson E, Elkhartoufi N, et al. Phenotypic spectrum and prevalence of INPP5E mutations in Joubert syndrome and related disorders. *Eur J Human Genet.* 2013;21(10):1074–8.
- Valente EM, Brancati F, Dallapiccola B. Genotypes and phenotypes of Joubert syndrome and related disorders. *Eur J Med Genet.* 2008;51(1):1–23.
- Doherty D. Joubert syndrome: insights into brain development, cilium biology, and complex disease. *Semin Pediatr Neurol.* 2009;16(3):143–54.
- Paprocka J, Jamroz E. Joubert syndrome and related disorders. *Neurol Neurochir Pol.* 2012;46(4):379–83.
- Srivastava S, Ramsbottom SA, Molinari E, Alkanderi S, Filby A, White K, et al. A human patient-derived cellular model of Joubert syndrome reveals ciliary defects which can be rescued with targeted therapies. *Hum Mol Genet.* 2017;26(23):4657–67.
- Wang SF, Kowal TJ, Ning K, Koo EB, Wu AY, Mahajan VB, et al. Review of Ocular Manifestations of Joubert Syndrome. *Genes.* 2018;9:12.
- Reiter JF, Leroux MR. Genes and molecular pathways underpinning ciliopathies. *Nat Rev Mol Cell Biol.* 2017;18(9):533–47.
- Berbari NF, O'Connor AK, Haycraft CJ, Yoder BK. The primary cilium as a complex signaling center. *Curr Biol.* 2009;19(13):R526–35.
- Malicki JJ, Johnson CA. The cilium: cellular antenna and central processing unit. *Trends Cell Biol.* 2017;27(2):126–40.
- Christensen ST, Pedersen LB, Schneider L, Satir P. Sensory cilia and integration of signal transduction in human health and disease. *Traffic (Copenhagen, Denmark).* 2007;8(2):97–109.
- Hildebrandt F, Otto E. Cilia and centrosomes: a unifying pathogenic concept for cystic kidney disease? *Nat Rev Genet.* 2005;6(12):928–40.
- Whewy G, Parry DA, Johnson CA. The role of primary cilia in the development and disease of the retina. *Organogenesis.* 2014;10(1):69–85.
- Fansa EK, Wittinghofer A. Sorting of lipidated cargo by the Arl2/Arl3 system. *Small GTPases.* 2016;7(4):222–30.
- Alkanderi S, Molinari E, Shaheen R, Elmaghloob Y, Stephen LA, Sammut V, et al. ARL3 mutations cause Joubert syndrome by disrupting Ciliary protein composition. *Am J Hum Genet.* 2018;103(4):612–20.
- Shaheen R, Schmidts M, Faqieh E, Hashem A, Lausch E, Holder I, et al. A founder CEP120 mutation in Jeune asphyxiating thoracic dystrophy expands the role of centriolar proteins in skeletal ciliopathies. *Hum Mol Genet.* 2015;24(5):1410–9.
- Roosing S, Romani M, Isrie M, Rosti RO, Micalizzi A, Musaev D, et al. Mutations in CEP120 cause Joubert syndrome as well as complex ciliopathy phenotypes. *J Med Genet.* 2016;53(9):608–15.
- Kahn RA, Der CJ, Bokoch GM. The ras superfamily of GTP-binding proteins: guidelines on nomenclature. *FASEB J.* 1992;6(8):2512–3.
- Gotthardt K, Lokaj M, Koerner C, Falk N, Giessel A, Wittinghofer A. A G-protein activation cascade from Arl13B to Arl3 and implications for ciliary targeting of lipidated proteins. *eLife.* 2015;4.
- Blacque OE, Perens EA, Boroevich KA, Inglis PN, Li C, Warner A, et al. Functional genomics of the cilium, a sensory organelle. *Curr Biol.* 2005; 15(10):935–41.
- Veltel S, Gasper R, Eisenacher E, Wittinghofer A. The retinitis pigmentosa 2 gene product is a GTPase-activating protein for Arf-like 3. *Nat Struct Mol Biol.* 2008;15(4):373–80.
- Evans RJ, Schwarz N, Nagel-Wolfrum K, Wolfrum U, Hardcastle AJ, Cheetham ME. The retinitis pigmentosa protein RP2 links pericentriolar vesicle transport between the Golgi and the primary cilium. *Hum Mol Genet.* 2010; 19(7):1358–67.
- Grayson C, Bartolini F, Chapple JP, Willison KR, Bhamidipati A, Lewis SA, et al. Localization in the human retina of the X-linked retinitis pigmentosa protein RP2, its homologue cofactor C and the RP2 interacting protein Arl3. *Hum Mol Genet.* 2002;11(24):3065–74.
- Schwarz N, Lane A, Jovanovic K, Parfitt DA, Aguila M, Thompson CL, et al. Arl3 and RP2 regulate the trafficking of ciliary tip kinesins. *Hum Mol Genet.* 2017;26(13):2480–92.
- Hanke-Gogokhia C, Wu Z, Gerstner CD, Frederick JM, Zhang H, Baehr W. Arf-like protein 3 (ARL3) regulates protein trafficking and Ciliogenesis in mouse photoreceptors. *J Biol Chem.* 2016;291(13):7142–55.
- Schrick JJ, Vogel P, Abuin A, Hampton B, Rice DS. ADP-ribosylation factor-like 3 is involved in kidney and photoreceptor development. *Am J Pathol.* 2006;168(4):1288–98.
- Mahjoub MR, Xie Z, Stearns T. Cep120 is asymmetrically localized to the daughter centriole and is essential for centriole assembly. *J Cell Biol.* 2010; 191(2):331–46.
- Wu C, Yang M, Li J, Wang C, Cao T, Tao K, et al. Talpid3-binding centrosomal protein Cep120 is required for centriole duplication and proliferation of cerebellar granule neuron progenitors. *PLoS One.* 2014;9(9):e107943.
- Comartin D, Gupta GD, Fussner E, Coyaude E, Hasegan M, Archinti M, et al. CEP120 and SPICE1 cooperate with CPAP in centriole elongation. *Curr Biol.* 2013;23(14):1360–6.
- Lin YN, Wu CT, Lin YC, Hsu WB, Tang CJ, Chang CW, et al. CEP120 interacts with CPAP and positively regulates centriole elongation. *J Cell Biol.* 2013; 202(2):211–9.
- Tsai JJ, Hsu WB, Liu JH, Chang CW, Tang TK. CEP120 interacts with C2CD3 and Talpid3 and is required for centriole appendage assembly and ciliogenesis. *Sci Rep.* 2019;9(1):6037.
- Xie Z, Moy LY, Sanada K, Zhou Y, Buchman JJ, Tsai LH. Cep120 and TACCs control interkinetic nuclear migration and the neural progenitor pool. *Neuron.* 2007;56(1):79–93.
- Wang H, Wang MX, Su N, Wang LC, Wu X, Bui S, et al. RNAscope for in situ detection of transcriptionally active human papillomavirus in head and neck squamous cell carcinoma. *Journal of visualized experiments : JoVE.* 2014;85.
- Wang F, Flanagan J, Su N, Wang LC, Bui S, Nielson A, et al. RNAscope: a novel in situ RNA analysis platform for formalin-fixed, paraffin-embedded tissues. *J Mol Diagnostics.* 2012;14(1):22–9.
- Holtan JP, Teigen K, Aukrust I, Bragadottir R, Houge G. Dominant ARL3-related retinitis pigmentosa. *Ophthalmic Genet.* 2019;40(2):124–8.
- Strom SP, Clark MJ, Martinez A, Garcia S, Abelazeem AA, Matynia A, et al. De novo occurrence of a variant in ARL3 and apparent autosomal dominant transmission of retinitis Pigmentosa. *PLoS One.* 2016;11(3):e0150944.
- Taverna E, Huttner WB. Neural progenitor nuclei IN motion. *Neuron.* 2010; 67(6):906–14.
- Hatten ME, Heintz N. Mechanisms of neural patterning and specification in the developing cerebellum. *Annu Rev Neurosci.* 1995;18:385–408.
- Chalupa LM, Gunhan E. Development of on and off retinal pathways and retinogeniculate projections. *Prog Retin Eye Res.* 2004;23(1):31–51.
- Hendrickson A. Development of Retinal Layers in Prenatal Human Retina. *Am J Ophthalmology.* 2016;161:29–35 e1.
- Hoon M, Okawa H, Della Santina L, Wong ROL. Functional architecture of the retina: development and disease. *Prog Retin Eye Res.* 2014;42:44–84.
- Krames ES. The role of the dorsal root ganglion in the development of neuropathic pain. *Pain Med (Malden, Mass).* 2014;15(10):1669–85.
- Kalchauer C, Barde YA, Thoenen H, Le Douarin NM. In vivo effect of brain-derived neurotrophic factor on the survival of developing dorsal root ganglion cells. *EMBO J.* 1987;6(10):2871–3.
- Piasecki BP, Siflow CD. The UNI1 and UNI2 genes function in the transition of triplet to doublet microtubules between the centriole and cilium in *Chlamydomonas*. *Mol Biol Cell.* 2009;20(1):368–78.
- Cuvillier A, Redon F, Antoine JC, Chardin P, DeVos T, Merlin G. LdARL-3A, a *Leishmania* promastigote-specific ADP-ribosylation factor-like protein, is essential for flagellum integrity. *J Cell Sci.* 2000;113(Pt 11): 2065–74.
- Li Y, Wei Q, Zhang Y, Ling K, Hu J. The small GTPases ARL-13 and ARL-3 coordinate intraflagellar transport and ciliogenesis. *J Cell Biol.* 2010;189(6): 1039–51.

47. Sharma A, Gerard SF, Olieric N, Steinmetz MO. Cep120 promotes microtubule formation through a unique tubulin binding C2 domain. *J Struct Biol.* 2018;203(1):62–70.
48. Sotelo C. Molecular layer interneurons of the cerebellum: developmental and morphological aspects. *Cerebellum* (London, England). 2015;14(5):534–56.
49. Ismail SA, Chen YX, Rusinova A, Chandra A, Bierbaum M, Gremer L, et al. Arl2-GTP and Arl3-GTP regulate a GDI-like transport system for farnesylated cargo. *Nat Chem Biol.* 2011;7(12):942–9.
50. Tucker RW, Pardee AB, Fujiwara K. Centriole ciliation is related to quiescence and DNA synthesis in 3T3 cells. *Cell.* 1979;17(3):527–35.
51. Pugacheva EN, Jablonski SA, Hartman TR, Henske EP, Golemis EA. HEF1-dependent Aurora a activation induces disassembly of the primary cilium. *Cell.* 2007;129(7):1351–63.

Publisher's Note

Springer Nature remains neutral with regard to jurisdictional claims in published maps and institutional affiliations.

Ready to submit your research? Choose BMC and benefit from:

- fast, convenient online submission
- thorough peer review by experienced researchers in your field
- rapid publication on acceptance
- support for research data, including large and complex data types
- gold Open Access which fosters wider collaboration and increased citations
- maximum visibility for your research: over 100M website views per year

At BMC, research is always in progress.

Learn more biomedcentral.com/submissions

