

RESEARCH

Open Access



# Assessing structural integrity of the pyramidal tracts with diffusion spectrum imaging to predict postoperative motor function in pediatric epilepsy patients with hemispherectomy

Huaqiang Zhang<sup>1†</sup>, Penghu Wei<sup>1†</sup>, Chao Lu<sup>1</sup>, Zhenming Wang<sup>2</sup>, Xiaotong Fan<sup>1</sup>, Yongzhi Shan<sup>1\*</sup> and Guoguang Zhao<sup>1,3,4,5,6,7</sup>

## Abstract

**Background:** Hemispherectomy is an effective treatment option for patients with drug-resistant epilepsy caused by hemispheric lesions. However, patients often have deterioration of their motor functions postoperatively. Diffusion spectrum imaging (DSI) was reliable in presenting the natural shape of the white matter fibers. At the same time, the natural sprawl pyramid tract (PT) might be more intuitive for predicting postoperative motor functions. Therefore, we assessed the motor functions by the natural shape revealed by DSI tractography.

**Methods:** Ten children with drug-resistant epilepsy who were candidates for hemispherectomy performed DSI PTs tractography and transcranial magnetic stimulation (TMS) for motor mapping. The motor function was evaluated with muscle strength and hand grasping capability. Pyramidal tract (PT) structural integrity and TMS mapping results were compared between patients who remained stable and those with deteriorated motor functions. Receiver operating characteristic (ROC) curves with PTs asymmetric ratio were analyzed to evaluate DSI tractography diagnostic value.

**Results:** All patients underwent DSI acquisition, while four patients successfully performed TMS. One patient had no response to TMS until the maximal machine output was reached. Four patients failed to perform TMS due to lacking cooperation. One patient was contraindicated to TMS. DSI successfully reconstructed the sharp angle fan-shaped PTs within the hemisphere. The accurate fiber distribution with fiber termination and thickness within the lesioned hemisphere was replicated with DSI tractography. No significance was found in patients' age, sex, seizure frequency, or medication between patients with stable or deteriorated postoperative motor functions. DSI effectively predicted postoperative motor function as stable with damaged PTs, mild deterioration with atrophied PTs, and intact PTs with contralateral innervation confirmed by intracranial stimulation. The area under the curve (AUC) of DSI tractography

<sup>†</sup>Huaqiang Zhang and Penghu Wei are the first co-authors.

\*Correspondence: shanyongzhi@xwhosp.org

<sup>1</sup> Department of Neurosurgery, Xuanwu Hospital, Capital Medical University, No. 45, Changchun Street, Xicheng District, Beijing 100053, China  
Full list of author information is available at the end of the article



was 0.84. According to ROC, the cut-off value of PTs asymmetric ratio was 11.5% with 100% sensitivity and 75% specificity. The sensitivity and specificity of TMS were 2/3 and 1/2, respectively.

**Conclusions:** The anatomic integrity of PTs with DSI tractography could effectively predict postoperative motor function after hemispherectomy. This enables neurosurgeons to inform patients and relatives about postoperative motor functions with direct morphological evidence of PTs to help them with their surgical decisions.

**Keywords:** Diffusion spectrum image, Epilepsy, Hemispherectomy, Motor function

## Background

Hemispherectomy was described independently by Dandy and Lhermitte as a radical treatment for malignant glioma of one hemisphere [1]. McKenzie first utilized it in treating drug-resistant epilepsy in 1938, which proved to be an effective treatment option for patients with drug-resistant epilepsy caused by hemispheric lesions. After that, functional anatomy was induced to reduce the complications associated with hemispherectomy [2]. Reported seizure-free rates of hemispherectomy range from 60% to 90% [3, 4].

However, this surgical procedure increases functional defects in the brain. Most patients often have deterioration of their motor functions. Although the ambulatory status of most patients is unchanged or could be returned to presurgical baseline postoperatively, many patients suffer a decrease in muscle strength of the distal part of the arm and hand dexterity [5]. This hemiparesis is often so severe that all active hand functions are lost. Clinically, patients and their families are usually concerned about postoperative motor function defects during counseling. Thus, the prediction of contralateral muscle strength and hand function is an essential step in the preoperative work-up for these patients. This highlights the crucial importance of optimal motor mapping before hemispherectomy.

As functional approaches, transcranial magnetic stimulation (TMS), functional magnetic resonance imaging (fMRI), and magnetoencephalography (MEG) were adopted for motor function localization. Nevertheless, the functional approaches have been denounced either for false activation of undesired movements or for the complex tasks difficult for toddlers to accomplish. At the same time, sedation would alter cerebral activity patterns [6]. As structural approaches, diffusion images could enable the identification of the status of the motor pathway without any tasks, and diffusion scalars such as fractional anisotropy (FA) and the fiber number within corticospinal tracts were reported to be higher on the affected side in patients whose postoperative muscle strength was reduced [7]. Nevertheless, direct morphological criteria such as the shape and the sprawl of the fibers for motor evaluation before hemispherectomy were not reported

because of the unquantified property of the diffusion tensor imaging (DTI) technique.

Diffusion spectrum imaging (DSI), a high angular resolution diffusion technique, can define more complex structures than DTI. Studies have shown that DSI could solve the cross and termination problem of the tractography [8], which was the disadvantage of DTI fiber reconstruction. In this report, we assessed the anatomic integrity of PTs with DSI to predict postoperative motor function in epilepsy cases candidate for hemispherectomy. We aimed to provide preliminary data on whether DSI is effective in motor mapping in clinical practices.

## Methods and materials

### Subjects

Drug-resistant epilepsy patients candidate for hemispherectomy were retrospectively recruited from the Neurosurgery Department of Xuanwu Hospital (Beijing, China) between March 2019 and November 2020. A multidisciplinary team of neurosurgeons, epileptologists, pediatricians, neurophysiologists, radiologists, and neuropsychologists carried out the presurgical evaluation. Children with hemiplegic epilepsy because of congenital or acquired hemispheric lesions and those who failed to control the disabling with fair trials of tolerable anti-seizure medications (ASMs) underwent hemispherectomy. Since hemispherectomy is the only and highly effective therapy to achieve seizure freedom of Rasmussen encephalitis [9], patients with Rasmussen encephalitis were excluded from this study. Lesion resection was reckoned to be a better functional outcome when preoperative motor mapping showed that only the lesioned hemisphere innervated the paralytic limbs. This study was approved by the Medical Ethics Committee of Xuanwu Hospital.

### DSI image acquisition

DSI studies were performed on a 3.0T scanner (GE SIGNA™ Premier, Chicago, USA) using a 48-channel head coil for all patients. A novel head stabilizer device was used to prevent head motion. In this trial, DSI data were acquired with equal spacing in q-space on a Cartesian grid in 259 directions, with a maximum  $b$ -value of 7000 s/mm<sup>2</sup>. The scan parameters were

as follows: repetition time (TR)=5548 ms, echo time (TE)=84.1 ms, field of view (FOV)= $224 \times 224 \text{ mm}^2$ , and voxel size= $2.0 \times 2.0 \times 2.0 \text{ mm}^3$  voxels. The flip angle was  $90^\circ$ . When the DSI data were acquired, they were analyzed by an experienced radiologist.

### DSI tractography

For the tractography of PTs, Digital Imaging and Communications in Medicine (DICOM) data were imported to DSI Studio (<http://dsi-studio.labsolver.org>). Reconstruction was performed by the generalized q-sampling imaging (GQI) method with orientation distribution functions output [10]. The diffusion sampling length with cerebral spinal fluid (CSF) calibration was 1.1. Before fiber reconstruction, regions of interest (ROIs) were drawn in orientation distribution function map images by a neurosurgeon with 20 years of experience within 3 days. The two overlapping parts were the final ROI.

An ROI was drawn at the precentral gyrus, cerebral peduncle, and medulla to guide tractography to perform the fiber tracking for a given lateral section of the PT. The PT was highlighted in the two-dimensional quantitative anisotropy (QA) map at these regions. A threshold was set at a value where the orientation signal best matches the profile of the structural T1 images. The angular threshold was 80 degrees, the step size was 0.4 mm, and the smoothing was 1.0. After reconstructing fiber tracts with DSI data, the PT structural integrity of motor fibers originating from the precentral gyrus was traced to the ventral horn of the spinal cord at the level of the occipital foramen area. Based on the PT and cerebral peduncle asymmetric study with poststroke hemiparetic patients, which showed the average affected/unaffected ratio was 72% [11], the atrophy PTs in the current study were defined by 72% or fewer fiber numbers of the PT compared to the unaffected side. Damaged PTs referred to those with non-continuous fibers between the precentral gyrus and medulla, whereas the symmetric PTs were considered intact.

### Pre and post-surgical evaluation

The preoperative evaluation comprised comprehensive seizure history, neurological examination, neuropsychological examination, long-term video electroencephalography, and neuroimaging. Since TMS was a commonly used technique, which could generate preoperative motor maps [12]. Children who had no contraindications also received a TMS motor mapping. The patients were tested sitting on their parent's lap, allowing them to watch a video or play with their toys. The TMS was performed with a simple figure-8 coil connected to a magnetic generator. The stimulation was applied to the Rolandic cortex, with an intensity initially set at 50% and

an increment of 10% of the machine output. The motor-evoked response (MEP) elicited by TMS was recorded by surface electromyography (EMG) from the bilateral abductor pollicis brevis. The stimulation was delivered until the EMG response was induced or the maximal output was reached.

Considering that complex clinical motor function examination may be difficult for children, the motor function was evaluated by the muscle strength with Medical Research Council (MRC) score and a simple grasping skill according to the Melbourne Assessment before surgery and at hospital discharge. A well-grasping ability was categorized with a fluent, accurate grasp of the pellet. The motor function was classified as "pre/postoperative no grasp," "grasping preserved," or "grasping lost." were evaluated preoperatively and at hospital discharge.

Hemiplegic patients with congenital malformation, dysplasia, or destructive lesions in the unilateral hemisphere that resulted in drug-resistant epilepsy underwent anatomic hemispherectomy. For those whose motor functions were normal, while TMS and bilateral robust intact PTs indicated unilateral innervation of upper limbs, stereoelectroencephalography (SEEG) investigation was considered for a better functional outcome with lesion resection.

### Surgical procedure

Patients underwent pathologic hemisphere removal with the approach of peri-insular hemispherectomy. The patient was supinely positioned, with a question mark skin incision. Under the neurosurgical microscope, the surgeon entered the lateral ventricle with an infra-insular window, followed by resecting the frontal, temporal, and occipital lobes along the circular sulcus. The mesial temporal structures, including the amygdala and hippocampus, were removed. Insular cortex resection was completed by subpial aspiration.

### Statistical analysis

Statistical analyses were performed using GraphPad Prism version 9.0 (San Diego, USA). Student's *t*-test and the Mann-Whitney U test were applied to identify the difference in clinical data between patients who were stable and those who deteriorated in motor function postoperatively. ROC curves were obtained and analyzed to identify the usefulness of motor mapping with DSI tractography. Sensitivity and specificity were compared between DSI tractography and TMS.

## Results

### Patients

We enrolled ten patients (age range: 2–14 years, mean age: 6.8 years, female: 5, male: 5) with hemispheric lesions

**Table 1** Clinical characteristics of the 10 children undergoing hemispherectomy

pat	age	sex	seizure frequency	ASMs	lesioned hemi	PT structural integrity		TMS	surgery	MRC score		grasping ability	motor function outcome
						healthy hemi	lesioned hemi			pre-OP	post-OP		
1	2	M	daily	2	L	robust	damaged	failed	hemispherectomy	4	4	pre/post no	stable
2	10	M	daily	4	L	robust	damaged	ipsi-lateral	hemispherectomy	4	4	pre/post no	stable
3	5	M	daily	3	L	robust	damaged	contra-lateral	hemispherectomy	4	4	preserved	stable
4	10	M	daily	4	R	robust	damaged	contraindicated	hemispherectomy	4	4	pre/post no	stable
5	7	F	weekly	2	L	robust	damaged	failed	hemispherectomy	4	4	preserved	stable
6	5	F	daily	3	R	robust	atrophied	ipsi-lateral	hemispherectomy	4	3	pre/post no	deteriorated
7	5	F	daily	4	L	robust	atrophied	failed	hemispherectomy	4	3	pre/post no	deteriorated
8	4	F	daily	3	R	robust	atrophied	failed	hemispherectomy	4	3	lost	deteriorated
9	6	F	weekly	2	R	robust	atrophied	no response	hemispherectomy	5-	2	lost	deteriorated
10	14	M	daily	3	L	robust	robust	contra-lateral	lesioned resection	5	5	preserved	stable

Abbreviations: ASMs anti-seizure medications, PT pyramidal tract, *lesioned hemi* lesioned hemisphere, *healthy hemi* healthy hemisphere, MRC score Medical Research Council (MRC) Scale for muscle strength

who completed clinical assessment and DSI tractography (Table 1). None of the patients had any complications due to the diffusion MRI scan. One patient received SEEG investigation since the preoperative evaluation highly suspected that the patient's motor function was unilaterally dominated. The SEEG recordings showed that the patient's seizures originated from the right frontal lobe. The intracranial stimulation with SEEG electrodes in the right precentral gyrus elicited tonic contraction of his left hand. Since the presurgical evaluation suggested a strong innervation of the right precentral gyrus in his left hand, the patient received removal of the right temporal, parietal, occipital, and frontal lobes anterior to precentral sulcus, leaving the precentral gyrus in the suit. All of the other patients underwent hemispherectomy. All patients were seizure-free since the surgery. There was no mortality and no severe postoperative complication requiring further surgical intervention in the study collective. No significance ( $p > 0.05$ ) was found in patients' age, sex, seizure frequency, or medication between the groups who remained stable or deteriorated in motor functions postoperatively.

#### **Tract fiber distribution and integrity**

For all patients, the PTs within the non-lesioned hemisphere were robustly intact between the precentral gyrus and ventral medulla. DSI tractography reconstructed the sharp angle fan-shaped PT distribution and crossed fibers within the centrum semiovale. Structural origins with a precentral gyrus folding pattern, termination of tract fibers, and anatomic features of motor fiber width and thickness along PTs were accurately replicated. In the lesioned hemisphere, five patients' PTs were damaged, four patients had continuous but atrophied PTs, and one had almost symmetric PTs between the two hemispheres (Fig. 1).

#### **TMS mapping**

All patients underwent preoperative TMS motor mapping. Five patients successfully underwent TMS, which predicted postoperative motor function in three children. One patient had no response from both hemispheres until the max machine output was reached. The other patient's TMS result demonstrated that his hand was unilaterally innervated, but he preserved his grasping ability after the hemispherectomy. Four children failed to perform TMS owing to a lack of cooperation. The other patient could not undergo TMS because of a contraindication with a skull defect.

#### **Postoperative motor function change**

The MRC motor score and grasping ability were evaluated between the pre-and postoperative state. Among

patients who underwent hemispherectomy, five patients with broken PTs within the lesioned hemisphere retained stable motor function postoperatively with an MRC score (Video 1 s a, b, and c in the online-only Supplementary material showed the pre-and post-operative walking of Patients 1, 2, and 3). Of these patients, three patients had no grasping ability pre-and postoperatively. Two hemiparetic patients with grasping capability pre-operatively preserved their hand function after the operation. Four patients with severe atrophy of PTs in the lesioned hemisphere experienced deterioration of muscle strength after hemispherectomy (see Video 1 s d in the online-only Supplementary material for pre-and post-operative walking for Patient 7). Besides, two of these patients whose hand functions were normal lost grasping ability postoperatively. One patient with intact PTs confirmed contralateral innervation of motor function by the intracranial stimulation and underwent lesion removal (Table 1 and Fig. 2). All patients remained seizure-free since hospital discharge.

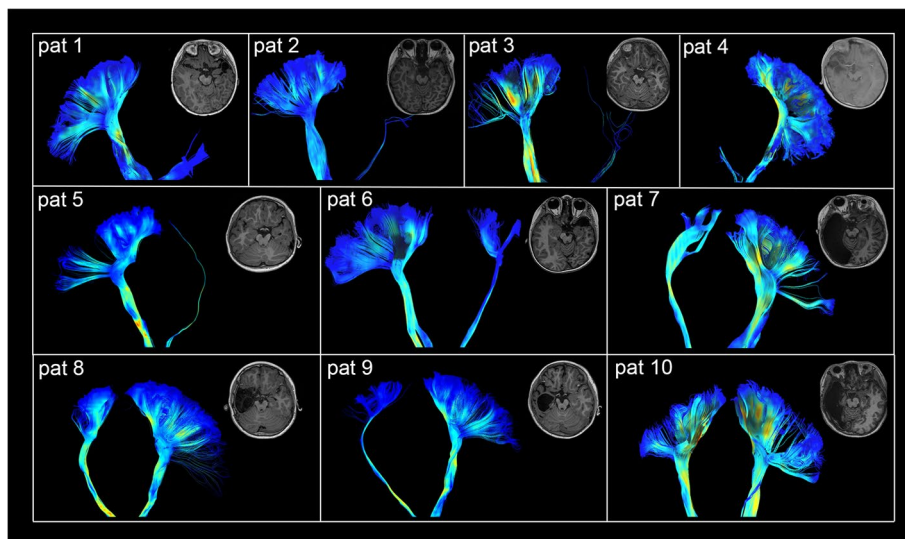
#### **Correlation between DSI tractography, TMS, and motor function**

The ROC of PT structural integrity was obtained to identify the usefulness of motor function mapping with DSI. The area under the ROC was 0.84 ( $p = 0.15$ ), suggesting that DSI tract integrity is a good approach to localizing motor innervation. According to the ROC, the cut-off value of the asymmetric ratio of PTs was 11.5%, leading to postoperative motor deterioration, with sensitivity being 100% and specificity being 75% (Fig. 3). The ROC analysis of TMS was not performed because 6/10 of the subjects failed or contraindicated to TMS or had no response till the maximal output of the machine was reached. Among the subjects with TMS performed, the sensitivity was 2/3, while the specificity was 1/2.

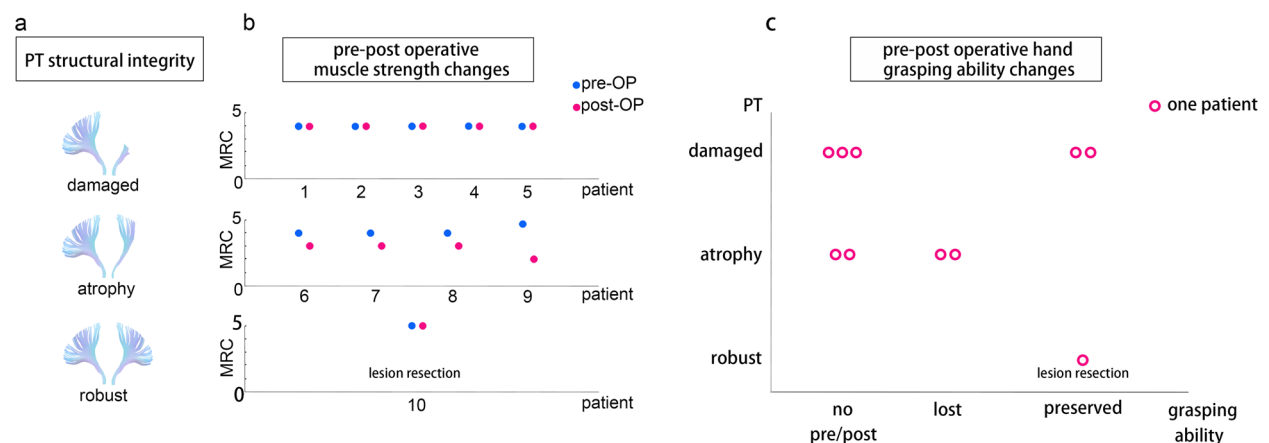
#### **Discussion**

Hemispherectomy has been used successfully for hemispherical drug-resistant epilepsy. A few studies have focused on predicting postoperative motor function with invasive [13] or non-invasive methods without direct morphologic change evidence [2, 14, 15]. Here, we presented a report on the evaluation of residual motor function by direct morphological reconstruction of PTs, which had higher sensitivity and specificity than TMS. With direct morphological evidence being provided, our methodology would be crucial for the caregivers and patients considering surgical decisions for hemispherectomy.

In clinical practice, fMRI, MEG, Wada test, and intraoperative motor mapping can be employed to examine the cerebral function of the intact and lesioned



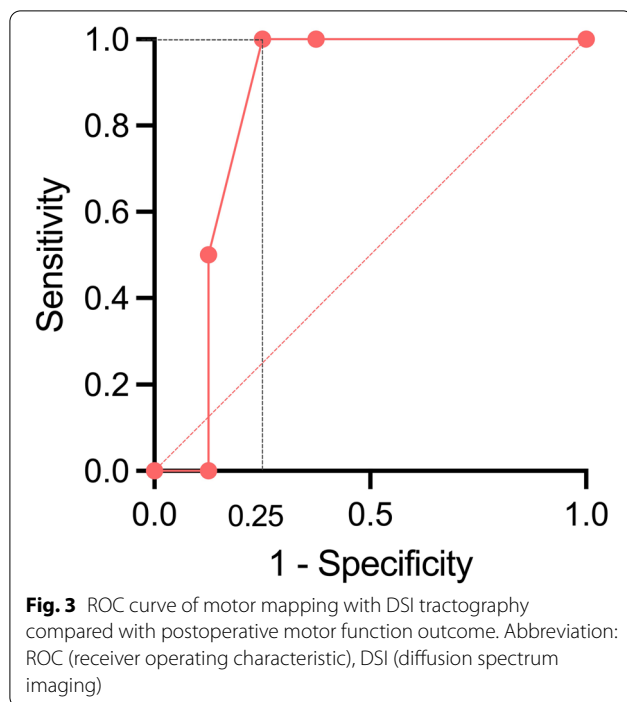
**Fig. 1** PT tractography of all the patients. Patients 1–5’s PTs were damaged. Patient 6–9’s PTs within the lesioned hemisphere were continuous but severely atrophied between the precentral gyrus and the spinal cord. Patient 10’s PTs were symmetric and robust between the two hemispheres. Abbreviation: pat (patient), PT (pyramidal tract)



**Fig. 2** DSI tractography of pyramidal tracts (PTs) and pre to post-operation motor function changes. **a** Illustration of PT tractography result: deficit of all the PT fibers was classified as “damaged”; continuous PTs with a deficit in most of the fibers were classified as “atrophied”; while the PTs within the lesioned hemisphere that were symmetric with the healthy hemisphere PTs were classified as “robust PTs.” **b** Patient 1–5 with broken PTs within lesioned hemisphere exhibited mild paralysis with muscle strength pre-operatively but remained stable postoperatively. Patients 6–9 with atrophied PTs exhibited paralysis with muscle strength pre-operatively and suffered mild deterioration postoperatively. Patient 10 exhibited symmetric and robust PTs between hemispheres, with contra-lateral innervation confirmed by intracranial stimulation. This patient received multilobar lesion resection and remained stable with muscle strength postoperatively. **c** Three patients with damaged PTs in the lesioned hemisphere had “no grasping ability” pre-operatively. Two of the patients with damaged PTs in the lesioned hemisphere were able to grasp pre-operatively. These patients’ postoperative hand grasping functions were stable compared with preoperative hand function. Four patients with atrophied PTs in the lesioned hemisphere could not grasp after the operation. Two of these patients who could grasp preoperatively lost their grasping ability postoperatively. The patient with robust symmetric PTs received multilobar lesion resection and remained stable in motor function after the operation. Abbreviation: PT (pyramidal tract), pre-OP (pre-operative), post-OP (post-operative)

hemisphere. Several authors have documented success using these methods to assess residual motor function. Wang et al. [16] reported 92.9% preoperative fMRI motor mapping sensitivity in healthy children. It

was reported that motor cortex mapping in children with epilepsy by resting-state fMRI revealed a sensitivity of 87.5% [17]. MEG is a helpful modality for preoperative localization of the motor cortex. Tarapore et al.



[12] reported that MEG imaging motor mapping successfully localized a motor site for index finger flexion comparable with direct cortical stimulation. In comparing the findings with previous studies, the current study suggested good sensitivity with DSI tractography for motor cortex mapping without task cooperation, which may be difficult for children with epilepsy. The feasibility of this approach could be explained by the finding that sensorimotor functional connectivity was PT-dependent in children with unilateral cerebral palsy [18].

DSI mapping predicted the motor function with higher sensitivity and specificity than TMS in the study. Although children under 10 years of age have higher MEP thresholds that decrease to adult levels by mid-adolescence [19], TMS was proven valuable and reliable in eliciting MEPs in children younger than three [20]. However, some patients failed to perform TMS or had no MEP response. Koudijs et al. [21] reported that 14/34 children had no motor responses in a TMS study of motor lateralization in children with epilepsy. The most obvious explanation for the lack of TMS responses in these children may be the antiepileptic medications, which may have had an inhibitory effect that resulted in the elevation of the cortex action threshold. In this study, DSI tractography could more precisely assess the motor function of children with hemispheric epilepsy than TMS mapping. Since DSI tractography does not need the cooperation and interferences of ASMs, it is

a possible useful probe in epileptic children's clinical management.

Several reports have correlated anatomical evidence with human motor function. The PT is the major neuronal pathway that mediates voluntary movements; hence, the preservation or recovery of the PT is mandatory for good recovery of impaired motor function [22]. This may be why most research chooses PTs' morphologic changes as an indicator for motor function recovery. Studies have reported that patients with a cerebral peduncle asymmetric ratio (contralateral/ipsilateral) > 1.5–2 would obtain an improved or unchanged motor function [3, 23, 24]. Govindan et al. [25] predicted an 8-year-old girl's motor function with DTI tractography before her hemispheric surgery. Nelles et al. [7] applied DTI fiber tracking in 34 patients, which found that FA of the affected PTs was significantly higher in patients with postoperative muscle-strengths loss than in patients without. Subsequently, Wang et al. [16] reported that bilaterally robust, symmetric PTs on DTI-FA maps were significantly associated with a severe postoperative motor decline in 25 patients. Consistent with these findings, we predicted post-surgical motor function accurately with DSI tractography in the present study. Moreover, DSI could solve the crossing and termination problem, for which fibers from the lateral and medial precentral regions could not be visualized in DTI fiber tracking [26]. DSI tractography could replicate the fan-shaped distribution of PTs between the lateral and superior precentral gyrus, with an accurate representation of the origin and termination of tract fibers and anatomic features of motor fiber width and thickness. Therefore, it could provide more neural pathway information, which may help to better inform patients and relatives about the motor outcomes after surgery.

Patient 10 with a hemispheric lesion involving the frontal, temporal, parietal, and occipital lobes but remains normal in motor function preoperatively. A little part of his precentral gyrus was affected in the infant intracranial hemorrhage due to vitamin K deficiency. However, his PTs remained intact during the development, confirmed by direct electrical stimulation following the SEEG procedure. Previous studies have also suggested that the infarct region but not the total infarction volume was directly linked to the PTs atrophy [11]. This case highlights the importance of preoperative motor function mapping, especially for those with normal motor function before the hemispherectomy. Lesion resection may also be practical after SEEG investigation or an alternative approach for those with predictors of function deterioration after surgery.

There are some limitations in the current study. Our clinical data were based on retrospective analysis of

hospital charts, which resulted in a broad classification of motor function. Further, assessing a functional outcome using an anatomical study demands solid justification. Additionally, DTI tractography provides another approach to studying the PT before hemispherectomy with a shorter image acquisition time. The small number of patients and lacking comparative studies with DTI may overstate DSI imaging modality for predicting motor preservation. Therefore, our findings need further validation by more rigorous case-control research with a larger patient group. DSI tractography requires a relatively long time for data acquisition, for which the sedation may limit its clinical application in children. However, DSI tractography seems more suitable and cost-effective than the Wada test and awake craniotomy, which is invasive and difficult to administer in children.

## Conclusions

In summary, the anatomic integrity of PTs with DSI tractography could predict postoperative motor function in children with hemispherectomy. This enables neurosurgeons to inform the patients and their caregivers about the postoperative motor function, which is vital in their surgical decision, with direct morphological evidence. Although it takes a relatively long time to acquire high-quality images, DSI tractography could be helpful for young patients who cannot cooperate with other tests or with patients receiving multiple and high doses of ASMs.

## Abbreviations

ASMs: Anti-seizure medications; AUC: Area under the curve; CSF: Cerebral spinal fluid; DICOM: Digital Imaging and Communications in Medicine; DSI: Diffusion spectrum imaging; DTI: Diffusion tensor imaging; EMG: Electromyography; FA: Fractional anisotropy; fMRI: Functional magnetic resonance imaging; FOV: Field of view; GQI: Generalized q-sampling imaging; MEG: Magnetoencephalography; MEP: Motor-evoked response; PT: Pyramidal tract; QA: Quantitative anisotropy; ROC: Receiver operating characteristic; ROIs: Regions of interest; SEEG: Stereoelectroencephalography; TE: Echo time; TMS: Transcranial magnetic stimulation; TR: Repetition time.

## Supplementary Information

The online version contains supplementary material available at <https://doi.org/10.1186/s42494-022-00115-y>.

**Additional file 1: Video 1s.** Pre- and post-operative walking status. (a, b, and c) Video records of patients 1, 2, and 3 showed equally walking pre- and post-operatively. (d) Patient 7 could carefully walk unassisted. However, the neurological examination revealed that muscle strength decreased by 1 grade on the MRC scale.

## Acknowledgments

We thank the Editage Group (<https://www.editage.cn>) for its linguistic assistance.

## Authors' contributions

HZ and PW designed the work, analyzed data and analysis, and drafted the work. CL contributed to the data acquisition. ZW contributed to data

acquisition and manuscript drafting. XF revised the results and the manuscript. YS and GZ designed the work, analyzed data, and revised the manuscript. All authors read and approved the final version of the manuscript.

## Funding

This work was supported by the National Natural Science Foundation of China (81871009, 81801288); the National Key R&D Program of China (2016YFC0103909), and the Translational and Application Project of Brain-inspired and Network Neuroscience on Brain Disorders, Beijing Municipal Health Commission (11000022T000000444685).

## Availability of data and materials

The datasets of the current study are available from the corresponding author upon reasonable request.

## Declarations

### Ethical approval and consent to participate

This study was approved by the Medical Ethics Committee of Xuanwu Hospital ([2022]094). Informed consent was obtained from all the children's parents included in the study.

### Consent for publication

All participants gave consent for publication.

### Competing interests

The authors certify that there is no conflict of interest with any financial organization regarding the material discussed in the manuscript.

### Author details

<sup>1</sup>Department of Neurosurgery, Xuanwu Hospital, Capital Medical University, No. 45, Changchun Street, Xicheng District, Beijing 100053, China. <sup>2</sup>Department of Radiology, Xuanwu Hospital, Capital Medical University, No. 45, Changchun Street, Xicheng District, Beijing 100053, China. <sup>3</sup>Beijing Institute for Brain Disorders, Capital Medical University, No. 10, West Tou Tiao, Outer You'an Men, Fengtai District, Beijing 100069, China. <sup>4</sup>National Medical Center for Neurological Diseases, Beijing 100053, China. <sup>5</sup>China International Neuroscience Institute, Beijing 100053, China. <sup>6</sup>Clinical Research Center of Epilepsy, Xuanwu Hospital, Capital Medical University, Beijing 100053, China. <sup>7</sup>Beijing Municipal Geriatric Medical Research Center, Beijing 100053, China.

Received: 24 August 2022 Accepted: 6 November 2022

Published online: 09 February 2023

## References

- Dandy WE. Removal of right cerebral hemisphere for certain tumors with hemiplegia: preliminary report. *J Am Med Assoc.* 1928;90(11):823–5.
- Du X, Chen S, Guan Y, Gu J, Zhao M, Li T, et al. Presurgical thalamus and brainstem shifts predict distal motor function recovery after anatomic Hemispherectomy. *World Neurosurg.* 2018;118:e713–e20.
- Du XY, Chen SC, Guan YG, Gu JJ, Zhao M, Li TF, et al. Asymmetry of cerebral peduncles for predicting motor function restoration in young patients before Hemispherectomy. *World Neurosurg.* 2018;116:e634–e9.
- Verdinelli C, Olsson I, Edelvik A, Hallbook T, Rydenhag B, Malmgren K. A long-term patient perspective after hemispherotomy—a population based study. *Seizure.* 2015;30:76–82.
- Van Empelen R, Jennekensschinkel A, Buskens E, Helders P, Van Nieuwenhuizen OJB. Functional consequences of hemispherectomy 2004;127(9):2071–9.
- Kim H, Chung CK, Hwang H. Magnetoencephalography in pediatric epilepsy. *Korean J Pediatr.* 2013;56(10):431–8.
- Nelles M, Urbach H, Sassen R, Schöne-Bake JC, Tschampa H, Träber F, et al. Functional hemispherectomy: postoperative motor state and correlation to preoperative DTI. *Neuroradiology.* 2015;57(11):1093–102.
- Granziera C, Schmähmann JD, Hadjikhani N, Meyer H, Meuli R, Wedeen V, et al. Diffusion Spectrum imaging shows the structural basis of functional cerebellar circuits in the human cerebellum in vivo. *PLoS One.* 2009;4(4):e5101.



9. Bien CG, Granata T, Antozzi C, Cross JH, Dulac O, Kurthen M, et al. Pathogenesis, diagnosis and treatment of Rasmussen encephalitis: a European consensus statement. *Brain*. 2005;128(3):454–71.
10. Yeh FC, Wedeen VJ, Tseng WY. Generalized q-sampling imaging. *IEEE Trans Med Imaging*. 2010;29(9):1626–35.
11. Mark VW, Taub E, Perkins C, Gauthier LV, Uswatte G, Ogorek J. Poststroke cerebral peduncular atrophy correlates with a measure of corticospinal tract injury in the cerebral hemisphere. *AJNR Am J Neuroradiol*. 2008;29(2):354–8.
12. Tarapore PE, Tate MC, Findlay AM, Honma SM, Mizuiri D, Berger MS, et al. Preoperative multimodal motor mapping: a comparison of magnetoencephalography imaging, navigated transcranial magnetic stimulation, and direct cortical stimulation. *J Neurosurg*. 2012;117(2):354–62.
13. Fujimoto A, Okanishi T, Nishimura M, Kanai S, Sato K, Enoki H. The Wada test might predict postoperative fine finger motor deficit after hemispherotomy. *J Clin Neurosci*. 2017;45:319–23.
14. Küpper H, Kudernatsch M, Pieper T, Groeschel S, Tournier JD, Raffelt D, et al. Predicting hand function after hemidisconnection. *Brain*. 2016;139(Pt 9):2456–68.
15. Choi JT, Vining EP, Mori S, Bastian AJ. Sensorimotor function and sensorimotor tracts after hemispherectomy. *Neuropsychologia*. 2010;48(5):1192–9.
16. Wang AC, Ibrahim GM, Poliakov AV, Wang PI, Fallah A, Mathern GW, et al. Corticospinal tract atrophy and motor fMRI predict motor preservation after functional cerebral hemispherectomy. *J Neurosurg Pediatr*. 2018;21(1):81–9.
17. Krishnamurthy M, You X, Sepeta LN, Matuska E, Oluigbo C, Berl MM, et al. Resting-state functional MRI for motor cortex mapping in childhood-onset focal epilepsy. *J Neuroimaging*. 2022;32(6):1201–10.
18. Simon-Martinez C, Jaspers E, Alaerts K, Ortibus E, Balsters J, Mailloux L, et al. Influence of the corticospinal tract wiring pattern on sensorimotor functional connectivity and clinical correlates of upper limb function in unilateral cerebral palsy. *Sci Rep*. 2019;9(1):8230.
19. Garvey MA, Mall V. Transcranial magnetic stimulation in children. *Clin Neurophysiol*. 2008;119(5):973–84.
20. Narayana S, Rezaie R, McAfee SS, Choudhri AF, Babajani-Feremi A, Fulton S, et al. Assessing motor function in young children with transcranial magnetic stimulation. *Pediatr Neurol*. 2015;52(1):94–103.
21. Koudijs SM, Leijten FS, Ramsey NF, van Nieuwenhuizen O, Braun KP. Lateralization of motor innervation in children with intractable focal epilepsy—a TMS and fMRI study. *Epilepsy Res*. 2010;90(1–2):140–50.
22. Jang SH. The role of the corticospinal tract in motor recovery in patients with a stroke: a review. *NeuroRehabilitation*. 2009;24(3):285–90.
23. Wakamoto H, Eluvathingal TJ, Makki M, Juhasz C, Chugani HT. Diffusion tensor imaging of the corticospinal tract following cerebral hemispherectomy. *J Child Neurol*. 2006;21(7):566–71.
24. Mullin JP, Soni P, Lee S, Jehi L, Naduvil Valappi AM, Bingaman W, et al. Volumetric analysis of cerebral peduncles and cerebellar hemispheres for predicting hemiparesis after Hemispherectomy. *Neurosurgery*. 2016;79(3):499–507.
25. Govindan RM, Chugani HT, Luat AF, Sood S. Presurgical prediction of motor functional loss using Tractography. *Pediatr Neurol*. 2010;43(1):70–2.
26. Fernandez-Miranda JC, Pathak S, Engh J, Jarbo K, Verstynen T, Yeh FC, et al. High-definition fiber tractography of the human brain: neuro-anatomical validation and neurosurgical applications. *Neurosurgery*. 2012;71(2):430–53.

Ready to submit your research? Choose BMC and benefit from:

- fast, convenient online submission
- thorough peer review by experienced researchers in your field
- rapid publication on acceptance
- support for research data, including large and complex data types
- gold Open Access which fosters wider collaboration and increased citations
- maximum visibility for your research: over 100M website views per year

At BMC, research is always in progress.

Learn more [biomedcentral.com/submissions](https://biomedcentral.com/submissions)

