

CASE REPORT

Open Access



# Novel variants of *SYNGAP1* associated epileptic encephalopathy: two cases report and literature review

Xingying Zeng<sup>1</sup>, Yong Chen<sup>2</sup>, Xiongying Yu<sup>2</sup>, Yuanyuan Che<sup>2</sup>, Hui Chen<sup>2</sup>, Zhaoshi Yi<sup>1</sup>, Jie Qin<sup>2</sup> and Jianmin Zhong<sup>2\*</sup>

## Abstract

**Background** *SYNGAP1* is a significant genetic risk factor for global developmental delay, autism spectrum disorder, and epileptic encephalopathy. De novo loss-of-function variants in this gene cause a neurodevelopmental disorder, for example, early-onset and drug-refractory seizures. We report two children with global developmental delay and epileptic encephalopathy, which are caused by *SYNGAP1* gene novel mutations, and drug treatment is effective.

**Case presentation** We report a boy and a girl presented with global developmental delay when they were young babies; as they grew up, cognitive impairment and social-communication disorder became more and more prominent; unfortunately, the patients developed into various seizure types, including eyelid myoclonia, myoclonic and absences when the boy was 1 year 8 months old and the girl was 3 years old. The two patients were found two previously unknown mutations by high throughput sequencing [c.3271\_ c.3272insT; (p.L1091L fs\*62), c.2515A > T (p.K839\*)] in exon 15 of the *SYNGAP1* in the proband. Sanger sequencing confirmed the heterozygous nature, and neither of their parents carried the same mutation. The girl treated with valproic acid and prednisone became seizure-free, and valproic acid and levetiracetam combined with clonazepam were influential in the other.

**Conclusions** The global developmental delay and epileptic encephalopathy of the children were probably due to the pathogenic mutation of the *SYNGAP1* gene, and prednisone and clonazepam may be effective in achieving seizure-free.

**Keywords** *SYNGAP1*, Epilepsy, Prednisone, Clonazepam, Case report

## Background

*SYNGAP1* (Gene ID: 8831 /OMIM: 603,384, Synonyms *SYNGAP*, *RASA5*, and *KIAA1938*) is located in the 6p21.3 chromosome. It encodes SynGAP protein, a Ras-GTPase activating protein that plays an important

role in synaptic signal transmission [1, 2]. Heterozygous loss-of-function variants in *SYNGAP1* cause autosomal mental retardation type 5 (MRD5; phenotype MIM 612621; gene/locus MIM 603384), and its common phenotypes include cognitive impairment, speech disorder, behavioral deficits, and epilepsy [3]. The loss-of-function variants of *SYNGAP1* are surprisingly common, with the incidence reported as 1–4/10,000 individuals, or approximately 0.5–4.0% of intellectual disability (ID) cases, making it one of the most common causes of ID with epilepsy [3, 4]. As *SYNGAP1* understanding and research progressed, people found more and more the diversity of disease range and

\*Correspondence:

Jianmin Zhong  
zhongjm@163.com

<sup>1</sup> Molecular Diagnostic Laboratory, Children's Hospital of Jiangxi Province, Nanchang 330006, China

<sup>2</sup> Department of Neurology, Children's Hospital of Jiangxi Province, Nanchang 330006, China



© The Author(s) 2023. **Open Access** This article is licensed under a Creative Commons Attribution 4.0 International License, which permits use, sharing, adaptation, distribution and reproduction in any medium or format, as long as you give appropriate credit to the original author(s) and the source, provide a link to the Creative Commons licence, and indicate if changes were made. The images or other third party material in this article are included in the article's Creative Commons licence, unless indicated otherwise in a credit line to the material. If material is not included in the article's Creative Commons licence and your intended use is not permitted by statutory regulation or exceeds the permitted use, you will need to obtain permission directly from the copyright holder. To view a copy of this licence, visit <http://creativecommons.org/licenses/by/4.0/>.

genetic variation related to *SYNGAP1* pathogenicity. Patients with pathogenic *SYNGAP1* variants were called *SYNGAP1*-related encephalopathy [3].

Although there are many reports about *SYNGAP1*-related encephalopathy in the medical community [2, 5, 6], we report that two children with ID and epilepsy carry the pathogenic variation of the *SYNGAP1* gene, and the interpretation of this locus has not been registered. Now the cases are shared, which enriches the heritage variation database and increases the choice of treatment options.

## Case presentation

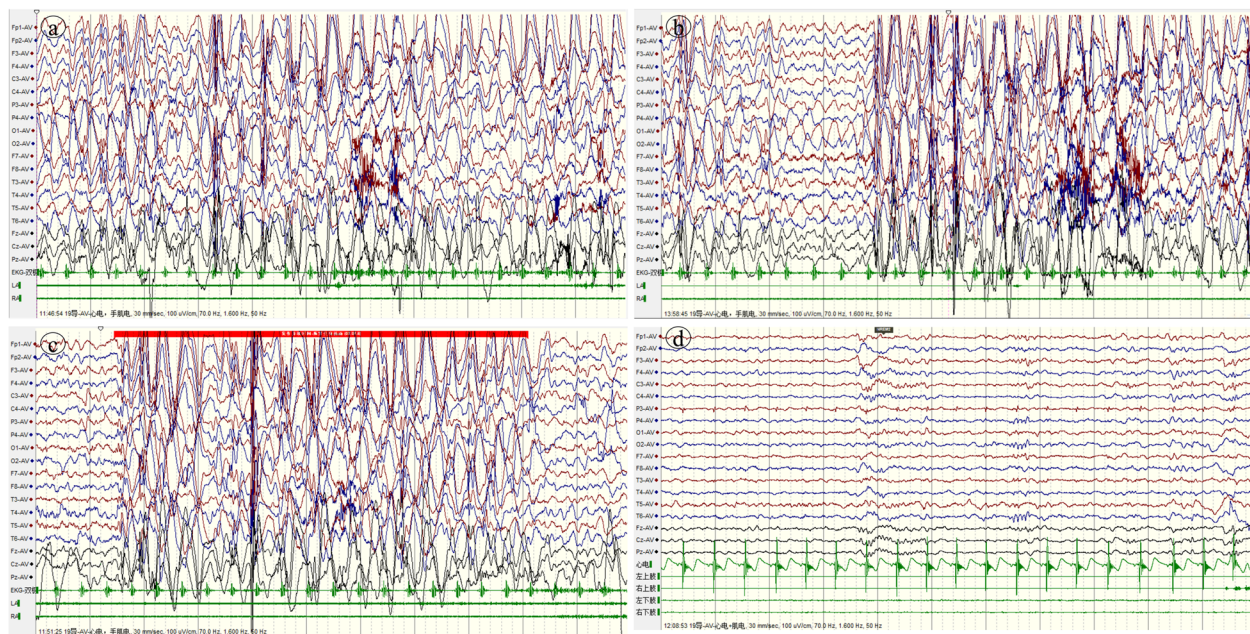
### Case 1

A 3-year-old Chinese girl of Han nationality, who expressed global developmental delay since childhood. She could look up at age of 6 months, walk independently at age of 33 months and only unconsciously shout "Mom and Dad" at age of 3. Her parents are not related, and her mother naturally conceived, had full-term childbirth, and had no history of hypoxia and asphyxia. At the age of 31 months, the girl suddenly appeared to have seizures in the form of a head tilted back and occurred in clusters, each for 3–4 s, several times a day. Sometimes she would stop suddenly and shake her body slightly when walking; occasionally, she nodded forward. Video electroencephalogram (VEEG) showed that seizure intervals were extensive 1.5–2.5 Hz, high amplitude slow spike slow waves, and focal spinous slow waves in the occipital or prefrontal region. Epileptic discharges can be seen in the seizure period, considering myoclonic seizures and atypical absence seizures (Fig. 1-a,b,c). MRI of the head showed no obvious abnormality. The Denver Developmental Screening Test (DDST) of this little girl suggests that she has global developmental abnormalities (thick motor development was equivalent to 13 months, fine motor adaptability was equal to 11 months, personal social development level was equivalent to 10 months, and language ability was equivalent to 10 months). High throughput sequencing (HTS) results showed *SYNGAP1*: c.3271 (exon15)\_ c. 3272 (exon15) InsT, p.L1091L FS \* 62. Sanger sequencing showed that the child carried *SYNGAP1* gene c.3271\_ c.3272 InsT heterozygous variation, and her parents were wild-type (Fig. 2). The GnomAD and HGMD database did not include this ectopic variant site (the last check was on May 18, 2022). The Uniport evaluated the ectopic variant site located in a highly conserved region (Fig. 3-a) and classified it as a "pathogenic" variant according to the ACMG variation classification standard (PVS1 + PS2 + PM2). Finally, the little girl was diagnosed with *SYNGAP1*-related encephalopathy. "valproic acid (VPA), 10 mg/kg/d" treatment was initially given. The number of seizures was decreased for a while

after she took medicine. After the dosage was increased to 15 mg/kg/d, the number of seizures was increased. The child had a variety of attack forms, the EEG discharge index exceeded 70%, the mental retardation was obvious, and even there were signs of regression. We combined the *SYNGAP1*-related encephalopathy, often complicated with refractory epilepsy and epileptic encephalopathy, so we gave the girl high-dose prednisone (60 mg/d). The seizure disappeared on the third day, and the EEG was normal after 2 weeks. The EEG was supplemented, as shown in Fig. 1-d. After that, prednisone was gradually reduced and stopped within 2 months. There was no seizure after follow-up for 1 year.

### Case 2

A boy was 3 years and 7 months old, and his motor language development was backward since birth; he looked up at age of 5–6 months, could walk independently at the age of 1 year and 6 months, and still couldn't speak at the age of 3 years and 7 months. His parents are not related, and his mother conceived naturally, gave birth naturally at full term, and had no history of hypoxia asphyxia. At 1 year and 7 months, the child was diagnosed with "autism spectrum disorder (ASD)" due to backward language development and went to the hospital. When he was 1 year and 10 months old, he had paroxysmal eyes upturning and blinking, with sluggish response and remission for several seconds, sometimes accompanied by head lowering. VEEG showed that spikes and slow waves were paroxysmal in all regions of the whole brain during an attack, and fast rhythm or multi spikes and slow waves were intermittent in the whole brain during sleep (Fig. 4-a,b). We considered the seizure type as eyelid myoclonus, atonic seizure, and absence. MRI of the head showed no obvious abnormality. HTS results revealed *SYNGAP1*: c.2515 (exon15) A > T, p.K839\*. Sanger sequencing showed that the child carried a heterozygous variant of *SYNGAP1* c.2515 (exon15) A > T, and his parents were wild-type (Fig. 5). The GnomAD and HGMD database did not include the ectopic variant site (the last check was on May 18, 2022). Some software predicted that this variant could terminate the amino acid translation in advance. The Uniport website evaluated that this ectopic variant site was located in a highly conserved region (Fig. 3-b) and was classified as a "pathogenic" variant according to the Annotation ACMG variation classification standard (PVS1 + PS2 + PM2 + PP3). *SYNGAP1*-related encephalopathy was diagnosed. After he took valproic acid, the attack frequency decreased slightly, eating could induce eyes upturning, and this situation still existed until 40 mg/kg/d. The number of seizures decreased after adding clonazepam



**Fig. 1** (EEG results of case 1): **a.** Before treatment, interictal sleep VEEG showed that in seizure interval there were extensive 1.5-2.5 Hz, high amplitude slow spike slow waves and focal spinous slow waves in occipital or prefrontal region; **b-c.** Epileptic discharges could be seen in the seizure period before treated, considering eyelid myoclonus and atypical absence seizures (In the picture b, the child sitting on the bed with her head slightly tilted back and her eyes blinking; in the picture c, the child sitting on the bed with her eyes looking forward without obvious movement); **d.** After treatment, EEG during sleep proved no obvious epileptiform discharge. Electromyogram: **a,b,c** (on both deltoid muscles) & **d** (on both deltoid muscles and both quadriceps femoris muscles)

at 2 years and 8 months. When clonazepam was added to 0.1 mg/kg/d, gait instability appeared, and his father refused to increase the dosage of clonazepam. Therefore, levetiracetam was added gradually to 35 mg/kg/d, but there was still an attack. Combined with the previous treatment of clonazepam, the curative effect of clonazepam was good, and the doctor added the child's clonazepam to 0.15 mg/kg/d. There was no obvious abnormality in EEG after 1 month (Fig. 4-c,d). The EEG was abnormal again after 3 months of follow-up. However, there was no obvious attack. Then added clonazepam to 0.2 mg/kg/d, the boy's EEG was normal after 3 months.

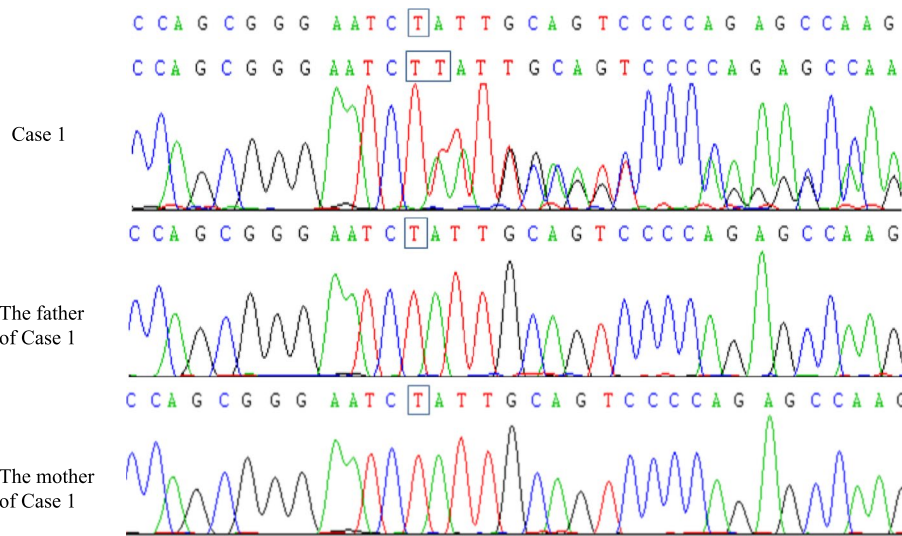
## Discussion

Case 1 had absence, eyelid myoclonus, and nodding, but our VEEG proved that her nodding was a non-epileptic seizure. The child did not have a tonic seizure and followed partial seizures. At present, epilepsy syndrome cannot be classified [7]. Case 2 had eyelid myoclonus, atonic attacks, and absence, accompanied with seizures induced by eating. Stülpnagel found that epilepsy associated with *SYNGAP1* mutation had the characteristics of food induction and eye closure sensitivity [6]. When simply looking up the *SYNGAP1*-related diseases in the Orphanet database, we would find more than 80% of the

patients have similar symptoms such as abnormal pain, speech and language development delay, generalized seizures, global development delay, and intellectual disability. The top three categories of phenotypes present in patients with sequence variants are global development delay, delayed speech, language development, and seizure in the Decipher database. The two children reported in this paper had extended developmental delay and intellectual disability since childhood, and the disease seriously impaired their language ability. They all had seizures with multiple seizure forms, highly similar to the clinical phenotypes of previously reported cases.

*SYNGAP1* is included in the developing disorder genes database and is the causative gene of intelligent developing disorder autosomal dominant type 5. The GnomAD PLI value is 1.0, which is sufficient evidence for haploinsufficiency. Among patients with an ACMG rating of P / LP, 39 / 50 of the variants included are frameshift and nonsense variants caused by small insertions and deletions in the Decipher database. At the same time, the Decipher database found that the highest phenotype frequency was global development delay in patients with sequence variants. In contrast, the phenotype was autistic behaviors in the patients with copy number variants (<https://www.deciphergenomics.org>). There were 205 patients rated P in the Clinvar database, of which





**Fig. 2** Sanger sequencing results of case 1. A denovo heterozygous frameshift mutation in the *SYNGAP1* gene: c.3271(exon15)\_c.3271(exon15) insT (p.leu1091Leufs\*62) (NM\_006772) in the proband of case1, and the mutation was not found in the her parents

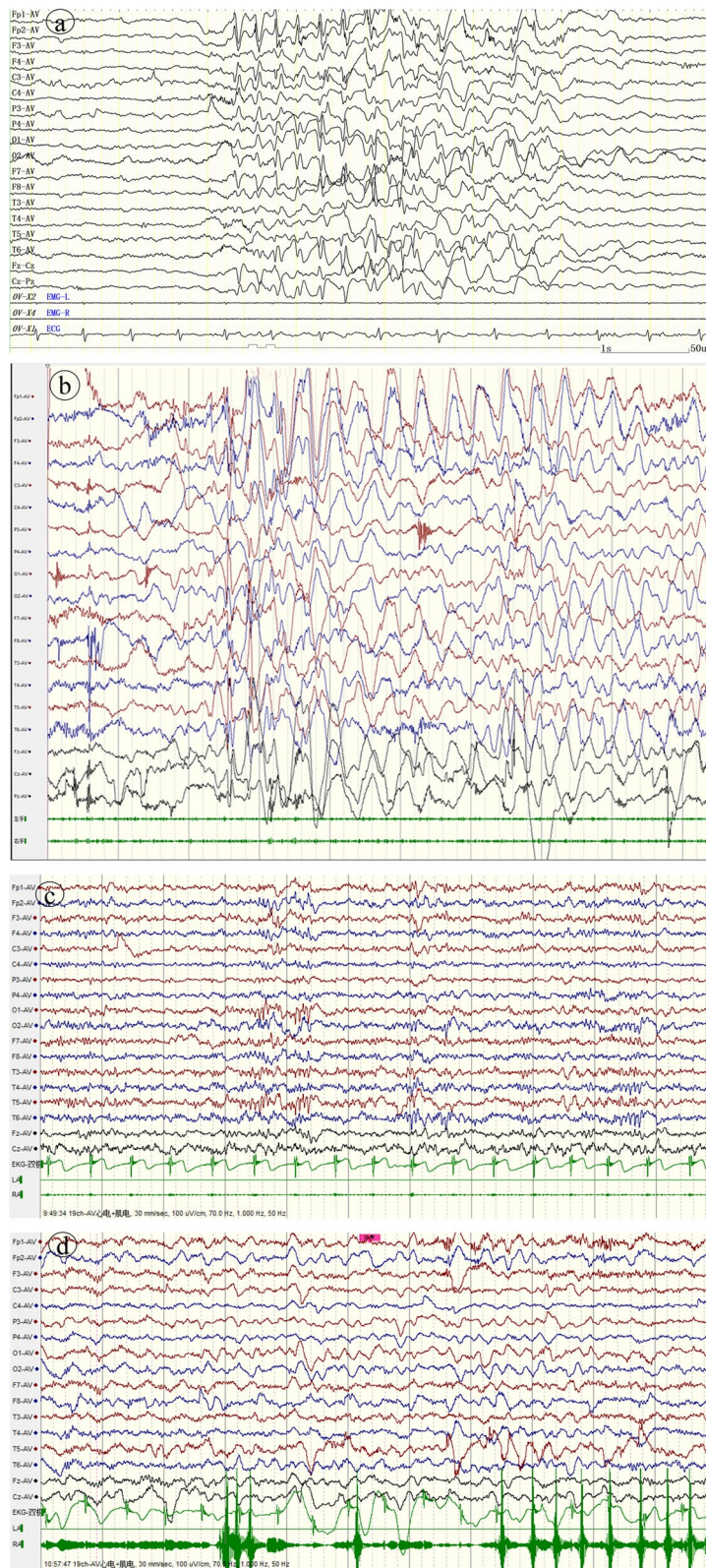
		1091
a	SYGP1_Human	AQKPRPSSGNLLQSPEPSYGPA
	SYGP1_Mouse	AQKPRPSSGNLLQSPEPSYGPA
	SYGP1_Rat	AQKPRPSSGNLLQSPEPSYGPA
	Pig	AQKPRPSSGNLLQSPEPSYGPA
	Bovine	AQKPRPSSGNLLQSPEPSYGPA
	Felis cat	AQKPRPSSGNLLQSPEPSYGPA
	Chimpanzee	AQKPRPSSGNLLQSPEPSYGPA
	Horse	AQKPRPSSGNLLQSPEPSYGPA
		839
b	SYGP1_Human	EPEQKMLSVNKSVSMLDLQGD
	SYGP1_Mouse	EPEQKMLSVNKSVSMLDLQGD
	SYGP1_Rat	EPEQKMLSVNKSVSMLDLQGD
	Pig	EPEQKMLSVNKSVSMLDLQGD
	Bovine	EPEQKMLSVNKSVSMLDLQGD
	Felis cat	EPEQKMLSVNKSVSMLDLQGD
	Chimpanzee	EPEQKMLSVNKSVSMLDLQGD
	Horse	EPEQKMLSVNKSVSMLDLQGD

**Fig. 3** Conservative analysis. Fig.3-a shows that the ectopic site of case1 is highly conserved in different species. Fig.3-b shows that the ectopic site of case 2 is highly conserved in different species

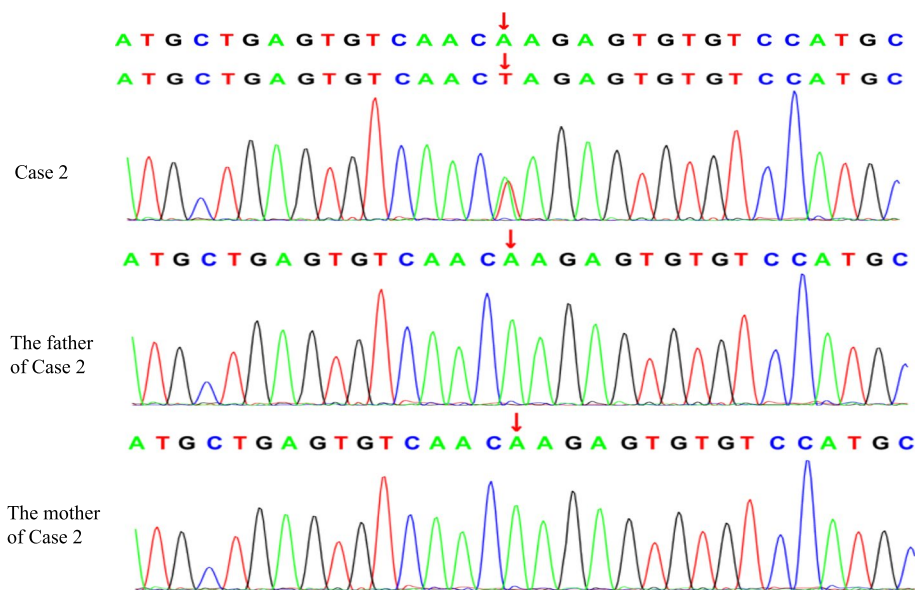
160/205 were frameshift and nonsense variants caused by small insertions and deletions (<https://www.ncbi.nlm.nih.gov/clinvar>). These data all support that the variant type described in this paper is pathogenic. After the Vercards Web, c.2515A>T was predicted to be harmful by multiple software, including mutation, CADD, Dann, fathmm\_MKL, Eigen, and Genocanyons. Unfortunately, there was

no Software prediction c.3271\_c. 3272insT (<http://159.226.67.237/sun/varcards>). Combined with the database data, variant sources, and variant types, the two variant sites reported in this paper are supported as newly discovered pathogenic mutation sites.

The *SYNGAP1* variation in two children reported by us appears in exon 15, which shows developmental



**Fig. 4** (EEG results of case 2): **a** Before treatment, spikes and slow waves in all regions of the whole brain could be seen in the EEG during the attack period; **b** Before treatment, fast rhythm or multi spike slow wave intermittent burst could be seen in EEG during seizure interval and awake period; **c-d** There was no obvious epileptiform discharge in EEG during sleep and awake after treatment. Electromyogram: on both deltoid muscles



**Fig. 5** Sanger sequencing results of case 2. A de novo heterozygous missense mutation in the *SYNGAP1* gene: c.2515(exon15) A > T (p.Lys839stop, 505) (NM\_006772) in the proband of case 2, and the mutation was not found in his parents

encephalopathy with epilepsy. Developmental encephalopathy belongs to a severe phenotype of *SYNGAP1*-related encephalopathy. It is said that the clinical manifestations of *SYNGAP1* encephalopathy patients with mutations in exons 5 to 19 are heavier than those in exons 1–4, and the prognosis of drug treatment is worse [2, 5]. We can understand this result by binding the SynGAP protein structure. SynGAP protein consists of N-terminal, C-terminal, and core region. The core region composed of C2, GAP, and SH3 is unchanged, and the N-terminal and C-terminal at both ends contain variable domains. At present, five N-terminals (A1, A2, B, C, and D) and four C-terminals ( $\alpha 1$ ,  $\alpha 2$ ,  $\beta$ , and  $\gamma$ ) have been found, and they constitute 20 subtypes [1, 8–10]. The variation of exons 1–4 will only affect the SynGAP-A subtype and will not affect other subtypes, while the amino acids encoded by exons 5–16 correspond to the fixed core region, which will affect SynGAP proteins of all subtypes, so the phenotype is relatively heavier.

Literature found that the mutations of *SYNGAP1*-related encephalopathy are all new mutations [2], and the case reported in this paper is also a new variant. De novo is the most common cause of ID, indicating that the genes causing ID are mostly single allele diseases. For the *SYNGAP1*, *SYNGAP1*<sup>-/+</sup> mouse model can appear with clinical phenotype, and homozygous mutation will cause embryonic death; On the other hand, it is difficult for patients with ID and ASD to get married and have children, which reduces the probability of inheritance of pathogenic variation [1].

It is reported in the literature that *SYNGAP1*-related encephalopathy is refractory, and usually, two or even six epilepsy drugs are used in combination. Valproic acid and lamotrigine are the most commonly used drugs. Polytherapy combinations resulting in seizure freedom included levetiracetam and topiramate, valproate and lamotrigine, and cannabidiol, valproate, with lamotrigine [3]. Although the literature reported that the prognosis of patients with exon 5 to exon 19 mutation was poor [2, 5], the therapeutic effect of our two children was acceptable. Our cases have various seizure forms, so the first choice is sodium valproate, a broad-spectrum antiepileptic drug, which does have the effect of reducing seizures. The child in case 1 finally controlled the seizure after adding a hefty prednisone dose, and the epileptic discharge disappeared. In the previous literature [2], a child with West syndrome caused by *SYNGAP1* mutation controlled the attack after using ACTH alone. The girl in this report doesn't have West syndrome, but the curative effect is excellent after using prednisone, which provides an idea for our future treatment. Although the child in case 2 was treated with valproic acid, levetiracetam, and clonazepam, combined with their medical history, we could find that clonazepam should be the most effective drug. However, why is clonazepam effective? The reason is found in the pathogenic mechanism of *SYNGAP1* mutation.

SynGAP protein is a brain-specific synaptic RasGTP activator protein 1, mainly expressed in the dendritic spines of cortical vertebral neurons, and plays a vital role in synaptic signal transmission [11]. The C-terminal



of SynGAP protein has a CC domain, which can bind to PDZ-containing proteins such as PSD95 [11]. Postsynaptic density protein (PSD) is a disc-shaped structure on the cytoplasmic side of the postsynaptic membrane of glutamate excitatory synapses in the mammalian central nervous system, which forms a complex with NMDAR and other substances. Under unstimulated baseline conditions, SynGAP was mainly located in the core region of PSD within 40 nm of the postsynaptic plasma membrane [12]. After depolarization, SynGAP is translocated from the core region of PSD to the external cytoplasmic part of the PSD complex [12]. Based on this feature, Walkup put forward the "slot" hypothesis. SynGAP occupies the slot containing PDZ protein in PSD [13]. When SynGAP in synapse decreases, more PDZ binding "sites" can be obtained. Other proteins will occupy these sites with the PDZ binding domain. Some of these proteins can stabilize and recruit AMPAR at a synapse, resulting in increased synaptic strength and imbalance of cell excitability. We all know that the imbalance of synaptic excitability (E) and inhibitory (I) balance is the basis of the pathogenesis of various central nervous system diseases [14]. If synaptic E/I balance tends to be excited, it will cause epilepsy [14]. Clonazepam is a drug to inhibit excitation, so it can be considered to add Clonazepam to *SYNGAP1*-related encephalopathy combined with drug-refractory epilepsy.

Since E/I imbalance is often associated with many neurological diseases, such as epilepsy, mental retardation, and autism, this explains the clinical characteristics of patients with *SYNGAP1*-related encephalopathy [15]. Because some patients are in a highly excited and irritable state, in addition to epilepsy and underdevelopment, there will be many behavioral problems, including ASD \ ADHD \ extreme risk-taking behaviors such as climbing and jumping from a height, as well as behavioral problems such as aggression, self-injury and temper tantrums, elevated pain threshold, difficulty eating and difficulty falling asleep, which perplex the guardians [14].

## Conclusions

In summary, we reported two epilepsy children with severe intellectual impairment and global growth retardation. HTS showed that the *SYNGAP1* gene was mutation in the two children, respectively c.3271\_ c.3272insT (p.L1091L fs\*62) and c.2515A > T (p.K839\*). Variants were verified by first-generation sequencing. This locus was a new variant in children, and there was no relevant report on HGMD. Through clinical characteristics and pathogenicity evaluation, this variant was pathogenic. These two children had multiple seizure forms and many EEG discharges. One

case was treated with sodium valproate combined with prednisone, and the other was treated with sodium valproate and levetiracetam combined with clonazepam. Their treatment was effective, which provided a treatment idea for the epilepsy of *SYNGAP1*-related encephalopathy in the future.

## Abbreviations

ACMG	The American College of Medical Genetics and Genomics
ACTH	Adrenocorticotropic hormone
ADHD	Attention-deficit hyperactivity disorder
ASD	Autism spectrum disorder
DDST	The Denver Developmental Screening Test
HGMD	The Human Gene Mutation Database
HTS	High throughput sequencing
ID	Intellectual disability
MRI	Magnetic resonance imaging
NMDAR	N-methyl-D-aspartate receptor
PSD	Postsynaptic density protein
VEEG	Video electroencephalogram
VPA	Valproate

## Acknowledgements

We are grateful to the patients for being willing to share their medical data.

## Authors' contributions

XZ: drafting the manuscript; Collection of case data. YC: Analysis or interpretation of data; YC, XY, and JQ: followed up with the patient. YC, ZY, and HC: The image processing. JZ: critically revised and gave final approval for publication of the paper. All authors have read and approved the manuscript.

## Funding

No funding was received for this study.

## Availability of data and materials

The datasets used and analyzed during the current study are available from the corresponding author upon reasonable request.

## Declarations

### Ethics approval and consent to participate

Written informed consent was obtained from the children's guardians to publish their cases, and the Research Ethics Committee of Children's Hospital of Jiangxi Province provided approval for this study (approval number is JXSETYY-YXKY-20210035).

### Consent for publication

Written informed consent was obtained from the guardians of the participants for the publication of this case report.

### Competing interests

None of the authors declared any conflict of interest.

Received: 26 July 2022 Accepted: 7 October 2022

Published online: 21 February 2023

## References

- Jeyabalan N, Clement JPSYNGAP1: Mind the Gap. *Frontiers in Cellular Neuroscience*. 2016, 10(32):1–27.
- Vlaskamp DRM, Shaw BJ, Burgess R, Mei D, Montomoli M, Xie H, et al. *SYNGAP1* encephalopathy: A distinctive generalized developmental and epileptic encephalopathy. *Neurology*. 2019;92(2):e96–107.
- Weldon M, Kilinc M, Holder JL, Rumbaugh G. The first international conference on *SYNGAP1*-related brain disorders: a stakeholder meeting

- of families, researchers, clinicians, and regulators. *J Neurodev Disord.* 2018;10(1):1–6.
4. Clement JP, Aceti M, Creson TK, Ozkan ED, Shi Y, J N, et al. Pathogenic SYNGAP1 mutations impair cognitive development by disrupting the maturation of dendritic spine synapses. *Cell.* 2012; 151(4):709–723.
  5. Mignot C, Stülpnagel Cv, Nava C, Ville D, Sanlaville D, Lesca G, et al. Genetic and neurodevelopmental spectrum of SYNGAP1-associated intellectual disability and epilepsy. *J Med Genet.* 2016;53(8):511–22.
  6. Stülpnagel Cv, Hartlieb T, Borggräfe I, Coppola A, Gennaro E, Eschermann K, et al. Chewing induced reflex seizures ("eating epilepsy ") and eye closure sensitivity as a common feature in pediatric patients with SYNGAP1 mutations: a review of literature and report of 8 cases. *Seizure. European Journal of Epilepsy.* 2018;65(01):131–7.
  7. Stephani U. The natural history of myoclonic-astatic epilepsy (Doose syndrome) and Lennox-Gastaut syndrome. *Epilepsia.* 2006;47(2):53–5.
  8. Gou G, Roca-Fernandez A, Kilinc M, Serrano E, ReigViader R, Araki Y, et al. SynGAP splice variants display heterogeneous Spatio-temporal expression and subcellular distribution in the developing mammalian brain. *J Neurochem.* 2020;154(6):618–34.
  9. Gamache TR, Araki Y, Haganir RL. Twenty Years of SynGAP Research: From Synapses to Cognition. *J Neurosci.* 2020;40(8):1596–605.
  10. Araki Y, Hong I, Gamache TR, Ju S, Collado TL, Shin JH, et al. SynGAP isoforms differentially regulate synaptic plasticity and dendritic development. *eLife.* 2020;9:e56273.
  11. Kilinc M, Creson T, Rojas C, Aceti M, Ellegood J, Vaissiere T, et al. Species-Conserved SYNGAP1 Phenotypes Associated with Neurodevelopmental Disorders. *Mol Cell Neurosci.* 2018;91:140–50.
  12. Yang Y, Tao-cheng JH, Reese TS, Dosemeci A. SynGAP moves out of the core of the postsynaptic density upon depolarization. *Neuroscience.* 2011;192:132–9.
  13. Walkup WG, Mastro TL, Schenker LT, Vielmetter J, Hu R, Iancu A, et al. A model for regulation by SynGAP- $\alpha$ 1 of binding of synaptic proteins to PDZ-domain "Slots" in the postsynaptic density. *eLife.* 2016;5:e16813.
  14. Andoh M, Ikegaya Y, Koyama R. Synaptic pruning by microglia in epilepsy. *J Clin Med.* 2019;8(12):2170–85.
  15. Eichler SA, Meier JC. E-I balance and human diseases - from molecules to networking. *Front Mol Neurosci.* 2008;1:2.

Ready to submit your research? Choose BMC and benefit from:

- fast, convenient online submission
- thorough peer review by experienced researchers in your field
- rapid publication on acceptance
- support for research data, including large and complex data types
- gold Open Access which fosters wider collaboration and increased citations
- maximum visibility for your research: over 100M website views per year

At BMC, research is always in progress.

Learn more [biomedcentral.com/submissions](https://biomedcentral.com/submissions)

