

CASE REPORT

Open Access



# Case report of antiseizure medicine-induced long QT syndrome and a literature review

Xiongying Yu, Jian Zha, Zhaoshi Yi, Xiaoyan Li, Hui Chen, Yuxin Xu and Jianmin Zhong\*

## Abstract

**Background:** To realize the clinical characteristics of long QT syndrome (LQTS) caused by antiseizure medicines (ASMs), and to improve the prevention and management of ASM-acquired QT syndrome.

**Case presentation:** A case of ASM-acquired QT syndrome was diagnosed and relevant literature was reviewed. The case was a 7-year-old boy who presented with a sudden onset of panic followed by changes in consciousness, with or without convulsions, lasting from tens of seconds to 3 min. The patient then received antiepileptic treatment with valproic acid, levetiracetam and oxcarbazepine and was seizure free for about a year. However, on August 12, 2021, his illness flared up again. Electroencephalogram (EEG) showed the background activity was slow, and no obvious epileptic discharge was detected. But electrocardiogram (ECG) showed a surprisingly prolonged QT interval (770 ms). Torsades de Pointes was found during Holter monitoring, while electrolyte levels were normal. The ECG recordings gradually returned to normal after stopping ASMs. For literature search, only 21 related papers were obtained after reading titles and full-texts of 105 English-language papers retrieved using keywords "acquired QT interstitial syndrome/acquired Long QT Syndrome (aLQTS)" and "anti-epileptic seizure drugs/ASMs", in the databases of Wanfang, CNKI, Pubmed, and other databases, from publication year 1965 to October 26, 2021. There are 12 types of drug-acquired LQTS caused by ASMs, most of which are Na<sup>+</sup> blockers, but LQTS caused by oxcarbazepine had not been reported previously.

**Conclusions:** ASMs such as oxcarbazepine can cause acquired LQTS. When Na<sup>+</sup> or K<sup>+</sup> channel blockers are used clinically, ECG should be reviewed regularly and abnormal ECG should be intervened in time to reduce iatrogenic accidents in patients with epilepsy.

**Keywords:** Antiseizure medicine, Long QT syndrome, Epilepsy

## Background

Long QT syndrome (LQTS) is a rare and often preventable cause of sudden cardiac death in young adults. Its prevalence is about 1/2500 [1]. According to the Practice Guidelines of the American Academy of Neurology, the risk of sudden unexpected death in epilepsy (SUDEP) in children is 0.22/1000 [2], accounting for 7%-17% of the mortality of patients with epilepsy. QT prolongation has been identified as one of the main mechanisms

of SUDEP, as it is associated with fatal arrhythmias. This condition may be further aggravated by antiepileptic treatment. Although the exact pathophysiological mechanism of SUDEP remains uncertain, there are growing concerns on the impairment of cardiac function, including arrhythmias caused by seizures. In addition, the potential role of antiepileptic seizure medicines (ASMs) has been proposed [3]. Although clinical data suggest that the use of most antiepileptic drugs does not cause an additional risk of QT prolongation, there is a lack of sufficient evidence that these drugs are completely risk-free for all patients [4]. At present, about 10 types of ASMs have been reported to induce acquired LQTS [5-7]. However, LQTS caused by oxcarbazepine has

\*Correspondence: zhongjm@163.com

Department of Neurology, Children's Hospital of Jiangxi Province, Nanchang 330006, China



© The Author(s) 2022. **Open Access** This article is licensed under a Creative Commons Attribution 4.0 International License, which permits use, sharing, adaptation, distribution and reproduction in any medium or format, as long as you give appropriate credit to the original author(s) and the source, provide a link to the Creative Commons licence, and indicate if changes were made. The images or other third party material in this article are included in the article's Creative Commons licence, unless indicated otherwise in a credit line to the material. If material is not included in the article's Creative Commons licence and your intended use is not permitted by statutory regulation or exceeds the permitted use, you will need to obtain permission directly from the copyright holder. To view a copy of this licence, visit <http://creativecommons.org/licenses/by/4.0/>.

not been reported before, and there is no consensus on ASMs associated with ECG changes and an arrhythmia risk. To advance the understanding of the ASM-acquired LQTS and improve the management of this condition, we report a case of oxcarbazepine-induced LQTS, combined with a review of related literature.

## Case presentation

### General information

The patient was a 13-year-old boy. In November 2015 at the age of 7, he experienced the first seizure, manifested as a sudden fear-like performance without an obvious cause in the awake state, followed by systemic rigidity, accompanied by limb twitching, which lasted for about 2–3 min, and the attack relieved naturally. Then the patient was sent to the local hospital, but the specific treatment was not clear. On March 9, 2016, the patient had a similar seizure. The presentation was the same as before, sometimes accompanied by secondary generalized tonic–clonic seizures. He was diagnosed as epilepsy (focal motor seizures with impaired awareness and focal progression to bilateral tonic–clonic seizures). On March 25, 2016, valproic acid treatment was given, with the dose gradually increasing to 5 ml, q12h (24 kg, 16 mg/kg per day). On July 20, 2016, seizures still occurred, and the therapy was changed to valproic acid + levetiracetam. On May 13, 2017, seizures occurred again, with condition of attention deficit hyperactivity disorder. Valproic acid (same as before) + oxcarbazepine (0.075, q12h initial dose, gradually increased to 0.15, q12h) treatment was given to the patient. This therapy continued for 1 year and 3 months till August 2018, when the patient's family refused to adjust the drug dose for the fear of side effects, but the patient still had one seizure every 5–12 months. On August 12, 2021, the clinical attack appeared again, showing sudden unconsciousness. The patient denied vomiting, chest tightness, chest pain or other symptoms before and after the attack. ECG recording in a third-level grade-A hospital in Xi'an showed that the QT/QTc (QT intervals corrected for heart rate) was obviously prolonged. No abnormality was found in EEG during the same period. Therefore, clinical suspicion of LQTS was made. The ASMs were immediately stopped (without permission from the doctor). Six days later, 2 times torsade de pointes (TdP) was revealed by Holter ECG monitoring, with QTc up to 770 ms, and the ECG also showed huge T wave. Considering the possibility of LQTS, doctors recommended to stop oxcarbazepine. In fact, they had stopped all antiepileptic drugs since August 12. In the evening of August 21, the patient again suffered the attack again, 4 times within 24 h, characterized by fear, holding others tightly, accompanied by vocalization and limb exertion. After 10 s, limb convulsions occurred,

which lasted for 2–3 min, and diminished automatically. The level of consciousness was normalized after the episode. Local emergency ECG examination showed that the QT interval was normal. Considering the establishment of epilepsy diagnosis and seizure frequency, the patient's guardian agreed to use ASMs again (valproic acid sustained release tablet 0.5, q12h, about 32 mg/kg per day + levetiracetam 0.25, q12h, about 16 mg/kg per day, weight 31 kg) and the clinical seizure was terminated. AmpSeq multiple PCR high-throughput sequencing performed on September 9 showed no LQTS-related gene variation. On September 22, no seizures occurred in the follow-up examination, and the ECG QT returned to normal.

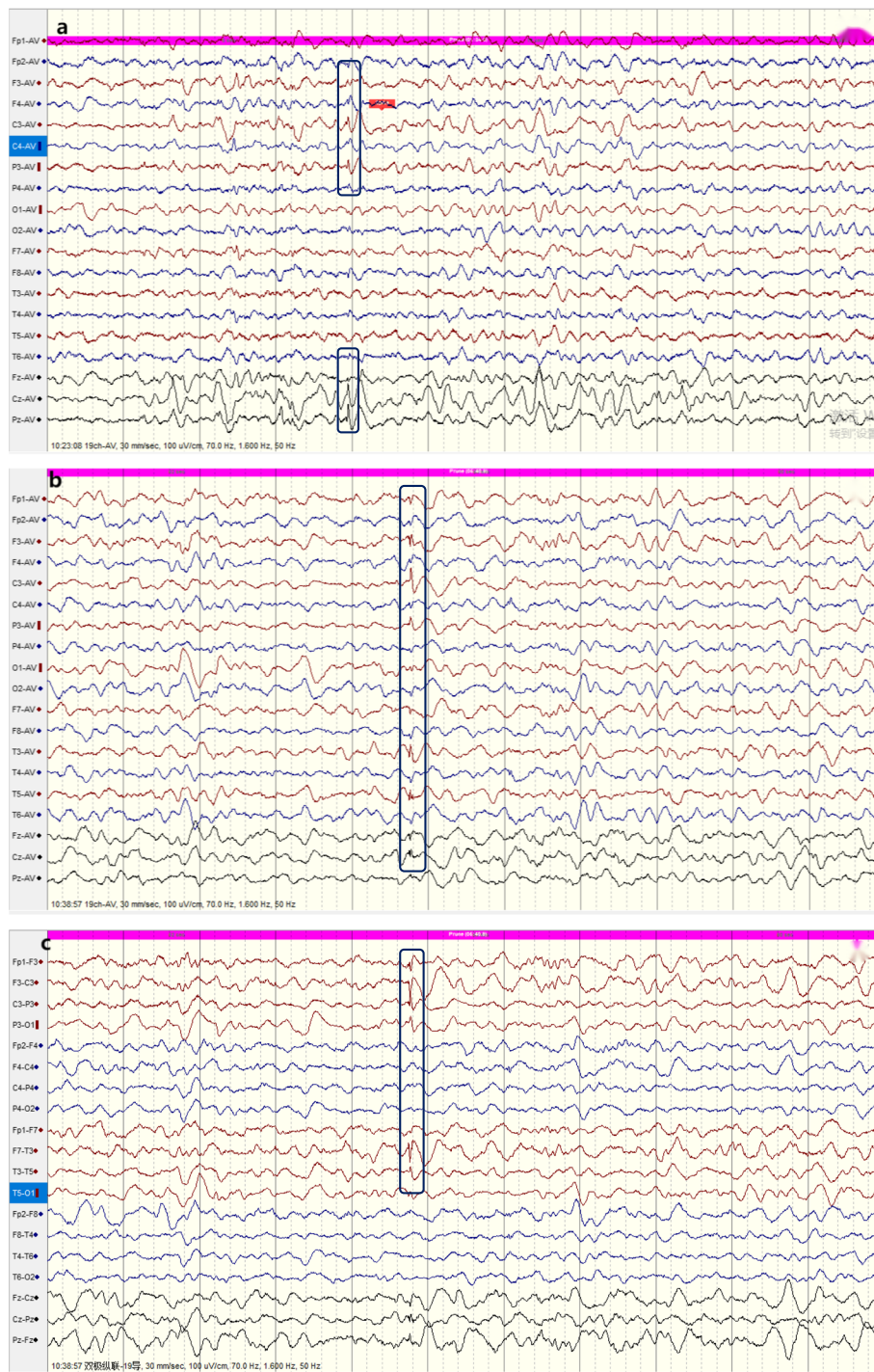
### Auxiliary examination

Blood routine tests in the Outpatient Department of Neurology on March 2016: WBC  $7.88 \times 10^9/l$ , N 47.14%, RBC  $4.03 \times 10^{12}/l$ , PLT  $187 \times 10^9/l$ , ALT 15.00 U/L, AST 25.00 U/L, BUN 3.40 mmol/l, CR 35.80  $\mu\text{mol}/l$ ,  $K^+$  4.80 mmol/l,  $Na^+$  140.00 mmol/l,  $Cl^-$  101.00 mmol/l,  $Ca^{2+}$  2.30 mmol/l,  $Mg^{2+}$  0.81 mmol/l,  $P^{3+}$  1.89 mmol/l. Parathyroid hormone concentration was within the normal range and hematuria metabolic disease screening showed normal results. ECG revealed sinus tachycardia; cranial MRI showed no abnormalities. On September 9, 2017, video-EEG showed spikes in the left central area, the parietal area and the parietal occipital area in the midline during the interictal phase (Fig. 1).

On August 12, 2021, prolonged QT/QTc (QTc 607 ms, huge T wave) was found. On August 19, Holter ECG showed that the longest QTc reached 770 ms (Fig. 2). The ECG QT interval returned to normal on August 21, and blood routine was reviewed again during the period (on August 18): WBC  $7.89 \times 10^9/l$ , N 61.40%, RBC  $4.42 \times 10^{12}/l$ , PLT  $294 \times 10^9/l$ , liver and kidney function (ALT 9.00 U/L, AST 17.00 U/L, BUN 2.90 mmol/l, CR 40.00  $\mu\text{mol}/l$ ), myocardial enzyme spectrum  $K^+$  4.30 mmol/l,  $Na^+$  146.00 mmol/l,  $Cl^-$  108.00 mmol/l,  $Ca^{2+}$  2.39 mmol/l,  $Mg^{2+}$  0.88 mmol/l, and  $P^{3+}$  1.47 mmol/l.

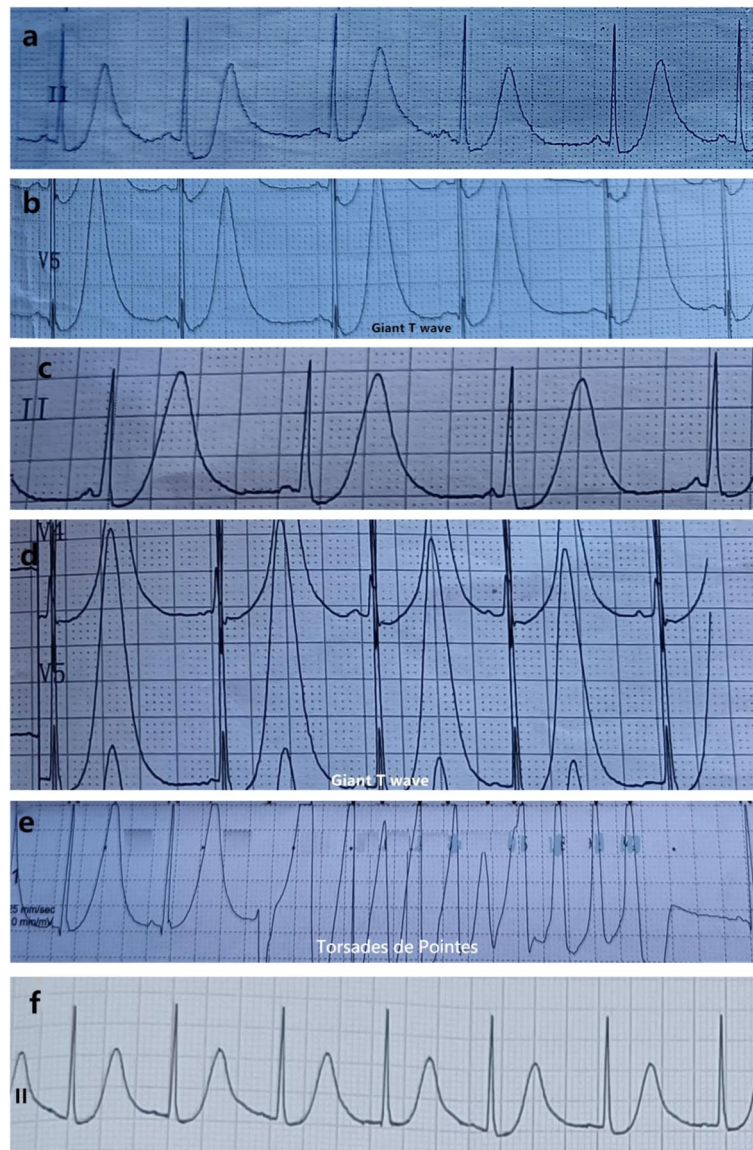### Literature retrieval

Literature published in English language was searched using terms "antiepileptic drugs/AEDs/ASMs" and "LQTS" in Wanfang, CNKI and Pubmed databases. Non-human studies were excluded (Fig. 3). A total of 105 papers were retrieved. After reading the abstracts and titles, only 24 papers remained, from which 3 were further excluded after reading the full-text. These studies involved 12 ASMs, including carbamazepine, lamotrigine, levetiracetam, clonazepam, valproic acid, esmlkazepine, lorazepam, thiopental sodium, midazolam, topiramate, pregabalin and pirenpanet. There were no reports of LQTS caused by oxcarbazepine. Twelve case reports and two studies reported LQTS caused by levetiracetam.



**Fig. 1** Interictal video EEG. **a** Sharp waves distributed in the left temporal, central and midline areas. **b, c** Average channel pattern (**b**) and longitudinal bipolar channel pattern (**c**) from the same interictal EEG. At the longitudinal bipolar channel pattern, phase inversion of C3 was seen. Rectangular boxes show sharp waves



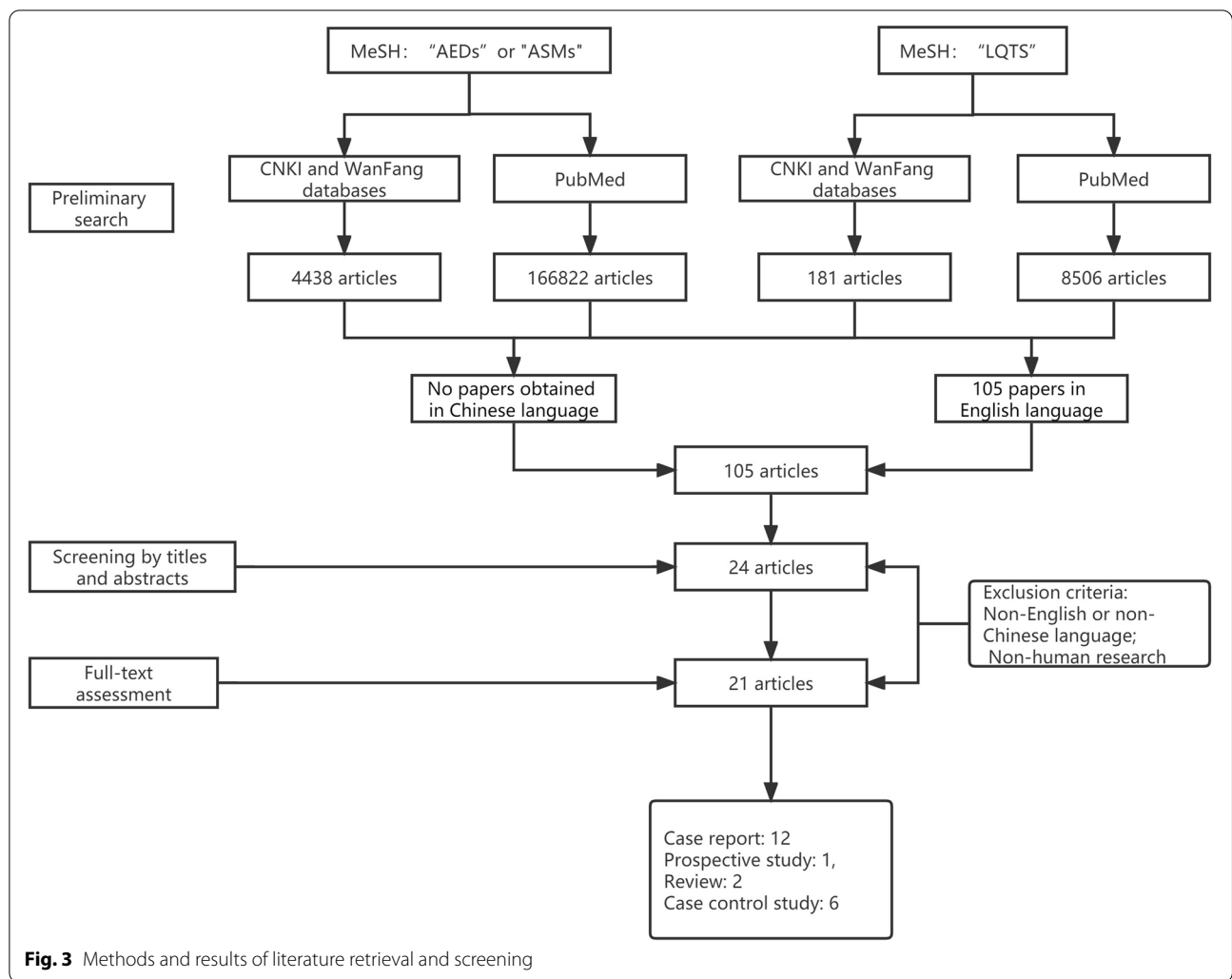


**Fig. 2** ECG recordings at four different periods. QTT interval is often measured on lead II or V5. **a, b** QTc of 607 ms and huge T waves detected by ECG on August 12, and changes in the S-T segment. **c, d** QTc of 558 ms detected by ECG on August 19. **e** Holter ECG monitoring of Torsades de Pointes on August 19. **f** ECG revealed QTc of 458 ms on August 21

## Discussion

LQTS is an electrophysiological disease of the heart, which is characterized by prolonged QT interval and abnormal T waves, and is directly associated with life-threatening TdP ventricular arrhythmias. Polymorphic ventricular arrhythmias characterized by self-limiting bursts of TdP can lead to clinical symptoms such as dizziness, palpitations, syncope, epilepsy, and even sudden cardiac death in severe cases. The diagnostic criteria for LQTS [8] are as follows: (1) 12-lead ECG detects QT interval  $\geq 480$  ms or risk score  $> 3.5$  according to the

Schwartz Long QT syndrome clinical diagnostic scoring system; and (2) in unexplained syncope, a repeated 12-lead ECG suggested QT interval  $\geq 460$  ms, with exclusion of secondary factors. The pathogenesises of LQTS include congenital LQTS caused by mutations in the genes encoding repolarization current ion channels, and acquired LQTS induced by other causes that increase depolarized  $\text{Na}^+$  and  $\text{Ca}^{2+}$  currents ( $i_{\text{Na}}$  and  $i_{\text{Ca}}$ , respectively) or decrease repolarized  $\text{K}^+$  currents ( $\text{IK}_s$ ,  $\text{IK}_r$  and  $\text{IK}_1$ ), prolong the duration of action potentials, and lead to a prolonged QT interval [9]. Studies have



**Fig. 3** Methods and results of literature retrieval and screening

linked acquired LQTS to electrolyte abnormalities, bradycardia, heart diseases, use of certain medications, subarachnoid hemorrhage, malnutrition, immunodeficiency virus and genetic predisposition. Among them, the drug-induced LQTS (diLQTS) is most commonly seen with antihistamines, antibiotics, antidepressants and pro-dynamic drugs [10].

The case in this report had suffered repeated stereotyped seizures for 6 years, and the main manifestations were focal motor seizures with disturbance of consciousness and focal generalization to generalized seizures. Video EEG showed epileptic discharges in the interictal period. The episode showed fear of panic-like expressions at first, followed by a decrease in consciousness level with / without limb jerks for 1–3 min. After anti-epileptic treatment, the seizures were reduced, and diagnosis of epilepsy was made. After 51 months of treatment with combined valproic acid and oxcarbazepine, the episodes decreased, with

an interval of 12 months to 18 months. However, his illness flared up again on August 12, 2021. ECG indicated a prolonged QT interval and a large T wave. ECG revealed prolonged QT interval for three times in different third-level grade-A hospitals, and QTc fluctuation within 553–770 ms. In addition, Holter dynamic electrocardiogram monitoring found two times Torsades de Pointes, which were consistent with the LQTS diagnostic criteria [8]. At the same time, blood biochemical measurements were normal, so electrolyte disorders were excluded. Both ASMs (valproic acid + oxcarbazepine) were stopped without permission from the patient’s family members. Nine days later, he suffered 4 attacks again. The QT/QTc (456–470 ms) returned to normal 10 days later, and huge T waves disappeared. ASMs (valproic acid 32 mg + levetiracetam) were taken again after consulting an epilepsy specialist, after which the seizures disappeared, and ECG performed 1 month later revealed no QT prolongation or

abnormal T wave changes. This indicates that the QT prolongation was related to oxcarbazepine.

The relationship between epilepsy and LQTS is complicated. Seizures can lead to QT prolongation [11–13], while LQTS can induce epileptic seizures; the two diseases can even be present together [14, 15]. Verrier et al. even proposed the concept of "epileptic heart", suggesting that recurrent seizures could lead to repeated surges of plasma catecholamines and hypoxemia that lead to electrical and mechanical dysfunction of cardiac cells. By searching the Wanfang, CNKI and Pubmed databases using "antiepileptic drugs /AEDs/ASMs" and "LQTS" as keywords, a total of 21 articles were retrieved, including 12 case reports, 1 prospective study, 2 reviews, and 6 case–control studies, covering a total of 12 ASMs [16–19]. Of the ASMs, sodium thiopental, chloronazepam, lorazepam, and levetiracetam have been reported to lead to LQTS; in particular, the Na<sup>+</sup>-blocker ASMs have more frequent inductions of LQTS. A case–control study concluded that most ASMs do not cause QT prolongation in children with epilepsy, including valproic acid, carbamazepine, and topiramate. However, the authors noted that the current evidence is insufficient to deny that ASMs may influence the cardiac repolarization process [20]. LQTS is caused by prolonged repolarization of cardiomyocytes, and its pathogenesis is mainly related to the decrease of fast delayed rectifier potassium currents and slow delayed rectifier potassium currents. The second is related to Na<sup>+</sup> current enhancement. ASMs mainly control seizures by enhancing GABA activity or blocking glutamate release. The voltage-gated Na<sup>+</sup>, Ca<sup>2+</sup>, and K<sup>+</sup> plasma channels are most common molecular targets of ASMs; therefore, ASMs may affect the cardiac myocyte repolarization, thereby prolonging the QT interval. The study of Danielsson et al. [4] showed that phenytoin, carbamazepine and phenobarbital may prolong the QT interval, with a higher plasma concentration associated with a greater risk. At the same time, ASMs may prolong the myocardial cell repolarization process through affecting myocardial cell depolarization in phase 2 and phase 3, which may lead to LQTS. Recent studies have found that diLQTS and TdP caused by many drugs (antihistamines, antipsychotics and antibiotics) with no structural similarities are caused by blockade of cardiac slow activation and delayed rectification of potassium current through voltage-gated potassium channels acting on Kv11.1 [10]. The  $\alpha$  subunit of this channel is encoded by the *KCNH2* gene and contains a total of 1159 amino acids, which is a member of the voltage-gated potassium channel family. It consists of six transmembrane domains (S1–S6). The S1–S4 domains form the voltage sensor domain (VSD) and respond to the changes of transmembrane voltage. The S5 and S6 domains form holes for selective filtration.

Although they are similar to some other voltage-gated potassium channels, Kv11.1 exhibits some unique inactivation mechanics, with closed, open and inactivated states. In addition, a prospective pharmacogenomics study found that ASMs that mainly block Na<sup>+</sup> channels are harmful in LQTS2, but have a protective effect in LQTS1 [21]. Therefore, diLQTS is not only related to the characteristics of the drug itself, but also to the genetic susceptibility of the host.

The treatment of acquired LQTS is based on the principle of "drug withdrawal, defibrillation, magnesium supplement, potassium supplement, pacing and medication". Among them, TdP and ventricular fibrillation are key pointers to immediate drug withdrawal, and they are also the main causes of death. diLQTS caused by ASMs should be alerted, and ASMs should be stopped immediately upon the co-occurrence of TdP and ventricular fibrillation [8–22]. The risk of TdP can be increased in the cases of prolonged QTc, t-U wave malformation and T wave electric alternation. For example, the active substance of oxcarbazepine is 10-hydroxy carbamazepine, whose oral peak time is 3–5 times that of oxcarbazepine, and its half-life is also significantly longer, about 12.48 h. Moreover, the latter has a strong affinity to red blood cells, and the intracellular concentration is 50% higher than the plasma level. Therefore, the biological half-life is significantly longer than the drug's half-life [23]. In addition, attention should be paid to drug interactions. The case of diLQTS caused by oxcarbazepine had not been reported previously. In addition, ECG still showed significant QTc extension (up to 770 ms) six days after stopping ASMs, a time significantly longer than the 5–7-h half-life (5–9 h in children) of the ASMs. This may be associated with valproic acid. On the 10th day, ECG showed normal activity, which indicates that the diLQTS caused by ASMs was reversible.

## Conclusions

Although the diLQTS caused by ASMs is extremely rare, there is still a high clinical risk and medical risk; therefore, during the diagnosis and treatment of epilepsy, we should pay more attention to identifying LQTS and analyzing its relationship with seizures. ASMs such as oxcarbazepine can cause acquired long QT syndrome. ECG should be reviewed regularly particularly when Na<sup>+</sup> or K<sup>+</sup> channel blockers are used, and abnormal ECG should be intervened in time to reduce iatrogenic accidents in patients with epilepsy.

## Abbreviations

ASMs: Antiepileptic seizure medicines; diLQTS: Drug-induced LQTS; LQTS: Long QT Syndromes; TdP: Torsade de pointes; VSD: Voltage sensor domain.

**Acknowledgements**

We appreciate the patient and his family for their support and understanding of the manuscript.

**Authors' contributions**

XY was responsible for data sorting and document compilation, Professor JZ was responsible for guiding and revising the literature, HC revised the paper, and other authors were responsible for data collection. All authors read and approved the final manuscript.

**Funding**

Not applicable.

**Availability of data and materials**

Not applicable.

**Declarations****Ethics approval and consent to participate**

This case report complied with the ethical guidelines of the Helsinki Declaration and was approved by the Human Ethics Committee of Jiangxi Children's Hospital (JXSETYY-YXKY-20220064). Written informed consent was obtained from the patient's guardian.

**Consent for publication**

Consent for publication was obtained from the legal guardian of the child, and the informed consent for publication form was signed.

**Competing interests**

The authors have no conflicts of interest to declare.

Received: 4 March 2022 Accepted: 11 May 2022

Published online: 15 November 2022

**References**

- Lahrouchi N, Tadros R, Crotti L, Mizusawa Y, Postema PG, Beekman L, et al. Transethnic genome-wide association study provides insights in the genetic architecture and heritability of long QT syndrome. *Circulation*. 2020;142(4):324–38.
- Abdel-Mannan O, Taylor H, Donner EJ, Sutcliffe AG. A systematic review of sudden unexpected death in epilepsy (SUDEP) in childhood. *Epilepsy Behav*. 2019;90:99–106.
- Christidis D, Kalogerakis D, Chan TY, Mauri D, Alexiou G, Terzoudi A. Is primidone the drug of choice for epileptic patients with QT-prolongation? a comprehensive analysis of literature. *Seizure*. 2006;15(1):64–6.
- Feldman AE, Gidal BE. QTc prolongation by antiepileptic drugs and the risk of torsade de pointes in patients with epilepsy. *Epilepsy Behav*. 2013;26(3):421–6.
- Yager N, Wang K, Keshwani N, Torosoff M. Phenytoin as an effective treatment for polymorphic ventricular tachycardia due to QT prolongation in a patient with multiple drug intolerances. *BMJ Case Rep*. 2015;2015:bcr2015209521 (Published 2015).
- Ciszowski K, Szpak D, Jenner B. The influence of carbamazepine plasma level on blood pressure and some ECG parameters in patients with acute intoxication. *Przegl Lek*. 2007;64(4–5):248–51.
- Dixon R, Job S, Oliver R, Tompson D, Wright JG, Maltby K, et al. Lamotrigine does not prolong QTc in a thorough QT/QTc study in healthy subjects. *Br J Clin Pharmacol*. 2008;66(3):396–404.
- Li CL, Liu WL, Gao YF. Current status of diagnosis and treatment of congenital and acquired long QT syndrome. *Prog Cardiovasc Dis*. 2021;42(5):385–91.
- Barsheshet A, Dotsenko O, Goldenberg I. Genotype-specific risk stratification and management of patients with long QT syndrome. *Ann Noninvasive Electrocardiol*. 2013;18(6):499–509.
- Baracaldo-Santamaría D, Llinás-Caballero K, Corso-Ramírez JM, Restrepo CM, Dominguez-Dominguez CA, Fonseca-Mendoza DJ, et al. Genetic and molecular aspects of drug-induced QT interval prolongation. *Int J Mol Sci*. 2021;22(15):8090.
- Verrier RL, Pang TD, Nearing BD, Schachter SC. The epileptic heart: concept and clinical evidence. *Epilepsy Behav*. 2020;105: 106946.
- Nishiguchi M, Shima M, Takahashi Y, Matsuoka H, Fujimoto S, Taira K, et al. A boy with occipital lobe epilepsy showing prolonged QTc in the ictal ECG. *No To Hattatsu*. 2002;34(6):523–7.
- Medford BA, Bos JM, Ackerman MJ. Epilepsy misdiagnosed as long QT syndrome: it can go both ways. *Congenit Heart Dis*. 2014;9(4):E135–9.
- Galtrey CM, Levee V, Arevalo J, Wren D. Long QT syndrome masquerading as epilepsy. *Pract Neurol*. 2019;19(1):56–61.
- Zaccara G, Lattanzi S. Comorbidity between epilepsy and cardiac arrhythmias: implication for treatment. *Epilepsy Behav*. 2019;97:304–12.
- Wilton NC, Hantler CB. Congenital long QT syndrome: changes in QT interval during anesthesia with thiopental, vecuronium, fentanyl, and isoflurane. *Anesth Analg*. 1987;66(4):357–60.
- Uçar HK, Arhan E, Serdaroglu A, Aydin K, Kazancioğlu A, Akkuzu E, et al. First description of QTc prolongation associated with clonazepam overdose in a pediatric patient. *Am J Ther*. 2018;25(5):e558–61.
- Crockford D. Re: lorazepam-induced prolongation of the QT interval in a patient with schizoaffective disorder and complete AV block. *Can J Psychiatry*. 2005;50(3):184–5.
- Rojano Martín B, Maroto Rubio M, Bilbao Ormazabal N, Martín-Sánchez FJ. Elderly patient with acquired long QT syndrome secondary to levetiracetam. *Neurologia*. 2011;26(2):123–5.
- Kwon S, Lee S, Hyun M, Choe BH, Kim Y, Park W, et al. The potential for QT prolongation by antiepileptic drugs in children. *Pediatr Neurol*. 2004;30(2):99–101.
- Auerbach DS, Biton Y, Polonsky B, McNitt S, Gross RA, Dirksen RT, et al. Risk of cardiac events in Long QT syndrome patients when taking antiseizure medications. *Transl Res*. 2018;191:81–92.e7.
- Guo JH. Interpretation of prevention and treatment suggestions for acquired long QT interval syndrome. *Chin J Cardiovasc Dis*. 2011;39(4):289–92.
- Antunes NJ, van Dijkman SC, Lanchote VL, Wichert-Ana L, Coelho EB, Alexandre Junior V, et al. Population pharmacokinetics of oxcarbazepine and its metabolite 10-hydroxycarbazepine in healthy subjects. *Eur J Pharm Sci*. 2017;109S:116–23.

**Ready to submit your research? Choose BMC and benefit from:**

- fast, convenient online submission
- thorough peer review by experienced researchers in your field
- rapid publication on acceptance
- support for research data, including large and complex data types
- gold Open Access which fosters wider collaboration and increased citations
- maximum visibility for your research: over 100M website views per year

**At BMC, research is always in progress.**

Learn more [biomedcentral.com/submissions](https://biomedcentral.com/submissions)

